# CLINICAL HEMATOLOGY ATLAS

Jacqueline H. Carr

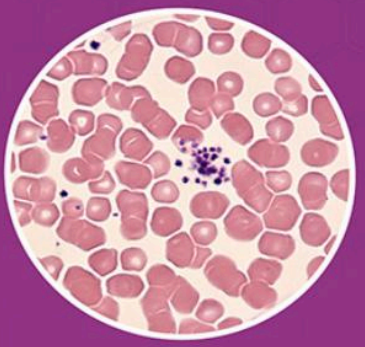

SIXTH EDITION

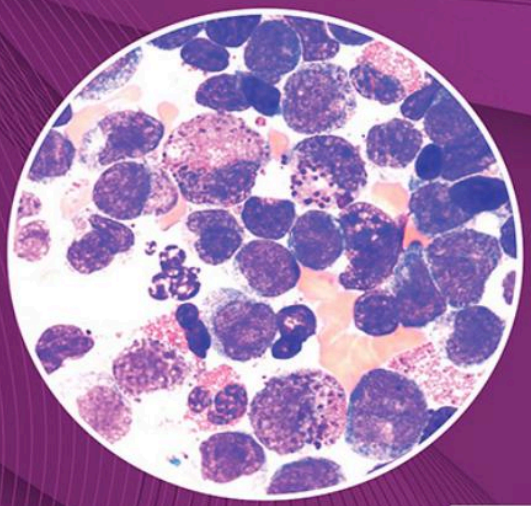

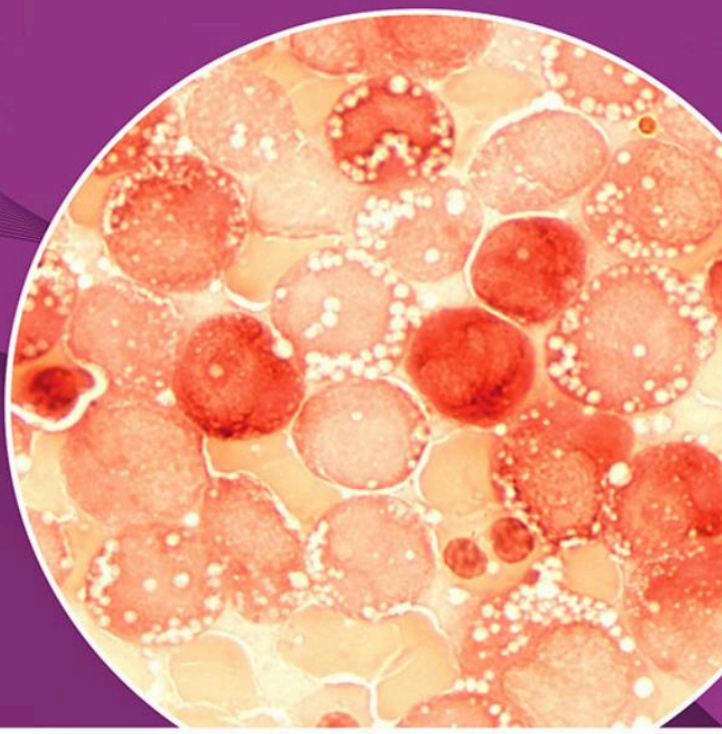

ELSEVIER

Evolve®

Student Resources on Evolve
*Access Code Inside*

Elsevier
3251 Riverport Lane
St. Louis, Missouri 63043

CLINICAL HEMATOLOGY ATLAS, SIXTH EDITION ISBN: 978-0-323-71192-0

**Copyright © 2022 by Elsevier, Inc. All rights reserved**.

No part of this publication may be reproduced or transmitted in any form or by any means, electronic or mechanical, including photocopying, recording, or any information storage and retrieval system, without permission in writing from the publisher. Details on how to seek permission, further information about the Publisher's permissions policies and our arrangements with organizations such as the Copyright Clearance Center and the Copyright Licensing Agency, can be found at our website: www.elsevier.com/permissions.

This book and the individual contributions contained in it are protected under copyright by the Publisher (other than as may be noted herein).

**Notice**

Practitioners and researchers must always rely on their own experience and knowledge in evaluating and using any information, methods, compounds or experiments described herein. Because of rapid advances in the medical sciences, in particular, independent verification of diagnoses and drug dosages should be made. To the fullest extent of the law, no responsibility is assumed by Elsevier, authors, editors or contributors for any injury and/or damage to persons or property as a matter of products liability, negligence or otherwise, or from any use or operation of any methods, products, instructions, or ideas contained in the material herein.

Previous editions copyrighted 2017, 2013, 2009, 2004 and 1999.

**Library of Congress Control Number: 2021943959**

*Content Strategist:* Heather Bays-Petrovic
*Senior Content Development Manager:* Luke Held
*Senior Content Development Specialist:* Maria Broker
*Publishing Services Manager:* Julie Eddy
*Senior Project Manager:* Abigail Bradberry
*Design Direction:* Ryan Cook

Printed in Canada

Last digit is the print number: 9 8 7 6 5 4 3 2 1



# ACKNOWLEDGMENTS

As in previous edition, the faculty and staff of the Department of Pathology and Laboratory Medicine, Indiana University School of Medicine have been supportive off this effort. An incredibly special thanks is owed to George Girgis who willingly and unselfishly shared his vast knowledge of microscopy in blood cell and body fluid morphology. Without his help and support, this edition of the Clinical Hematology Atlas would not have been possible. A special thanks to Linda Marler and Jean Siders who once again allowed us to publish their microbiology images.

The professionals at Elsevier who been incredibly patient during the last year as this atlas began to come to life. The following people deserve my gratitude for their kind assistance and advice:

Heather Bays-Petrovic, Content Strategist

Abigail Bradberry, Senior Project Manager

Maria Broeker, Senior Content Development Specialist

# CONTENTS


## Section 1 Introduction

1 Introduction to Peripheral Blood Film Examination 1

## Section 2 Hematopoiesis

2 Hematopoiesis 11
3 Erythrocyte Maturation 17
4 Megakaryocyte Maturation 31
5 Neutrophil Maturation 41
6 Eosinophil Maturation 55
7 Basophil Maturation 65
8 Monocyte Maturation 69
9 Lymphocyte Maturation 79

## Section 3 Erythrocytes

10 Variations in Size and Color of Erythrocytes 89
11 Variations in Shape and Distribution of Erythrocytes 93
12 Inclusions in Erythrocytes 107
13 Diseases Affecting Erythrocytes 115

## Section 4 Leukocytes

14 Nuclear and Cytoplasmic Changes in Leukocytes 131
15 Acute Myeloid Leukemia 141
16 Precursor Lymphoid Neoplasms 161
17 Myeloproliferative Neoplasms 165
18 Myelodysplastic Syndromes 175
19 Mature Lymphoproliferative Disorders 185
20 Morphologic Changes After Myeloid Hematopoietic Growth Factors 195

## Section 5 Miscellaneous

21 Microorganisms 199
22 Miscellaneous Cells 207
23 Normal Newborn Peripheral Blood Morphology 219
24 Body Fluids 223

**Glossary 245**
**Index 265**

CHAPTER 1

# INTRODUCTION TO PERIPHERAL BLOOD FILM EXAMINATION

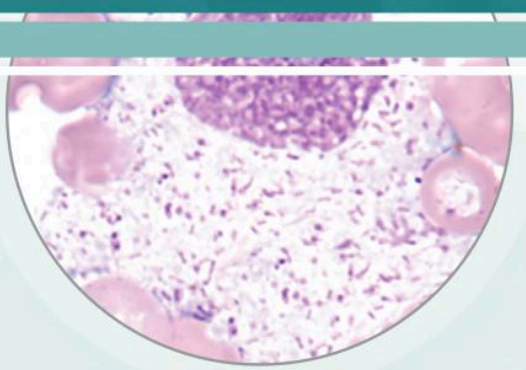

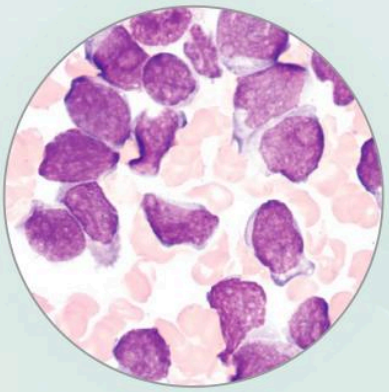

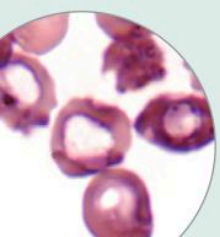

A properly prepared blood film is essential to accurate assessment of cellular morphology. A variety of methods are available for preparing and staining blood films, the most common of which are discussed in this atlas. It is beyond the scope of this atlas to discuss other methodologies; however, detailed descriptions of these procedures can be found in textbooks on hematology, such as *Rodak's Hematology: Clinical Principles and Applications*, sixth edition.

## WEDGE FILM PREPARATION

### MAKING THE PERIPHERAL BLOOD FILM

Although some automated analyzers prepare and stain blood films according to established criteria, manual blood film preparation is still used in many places. The wedge film is a convenient and commonly used technique for making peripheral blood films. This technique requires at least two 3 × 1-inch (75 × 25-mm) clean glass slides. High-quality, beveled-edge microscope slides are recommended. One slide serves as the blood film slide, and the other as the spreader slide. These can then be reversed to prepare a second film. A drop of ethylenediaminetetraacetic acid (EDTA) anticoagulated blood about 3 mm in diameter is placed at one end of the slide. Alternatively, a similar size drop of blood directly from a finger or heel puncture is acceptable. The size of the drop of blood is important. Too large a drop creates a long or thick film, and too small a drop often makes a short or thin film. In preparing the film, the technician holds the pusher slide securely in front of the drop of blood at a 30- to 45-degree angle to the film slide (Figure 1.1A). The pusher slide is pulled back into the drop of blood and held in that position until the blood spreads across the width of the slide (Figure 1.1B). It is then quickly and smoothly pushed forward to the end of the film slide, creating a wedge film (Figure 1.1C). It is important that the whole drop of blood is picked up and spread. Moving the pusher slide forward too slowly accentuates poor leukocyte distribution by pushing larger cells, such as monocytes and granulocytes, to the very ends and sides of the film. Maintaining a consistent angle between the slides and an even, gentle pressure is essential. It is frequently necessary to adjust the angle between the slides to produce a satisfactory film. For higher than normal hematocrit, the angle between the slides must be lowered so that the film is not too short and thick. For extremely low hematocrit, the angle must be raised. A well-made peripheral blood film (Figure 1.2) has the following characteristics:

1. About two-thirds to three-fourths of the length of the slide is covered by the film.
2. It is slightly rounded at the feather edge (thin portion), not bullet shaped.
3. Lateral edges of the film should be visible. The use of slides with chamfered (beveled) corners may facilitate this appearance.
4. It is smooth without irregularities, holes, or streaks.
5. When the slide is held up to light, the feather edge of the film should have a "rainbow" appearance.
6. The whole drop is picked up and spread.

Figure 1.3 shows examples of unacceptable films.

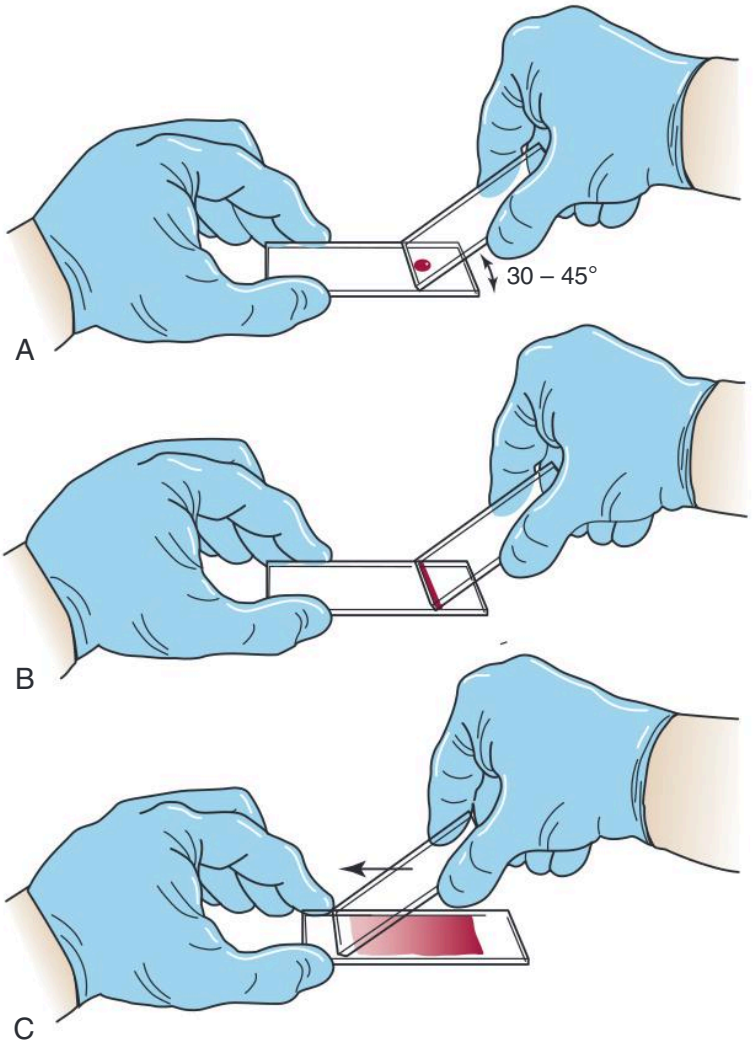


**FIGURE 1.1** Wedge technique of making a peripheral blood film. (A) Correct angle to hold spreader slide. (B) Blood spread across width of slide. (C) Completed wedge film.
(From Keohane E.A., Smith L., Walenga J. (Eds.) (2016). *Rodak's hematology: clinical principles and applications*. (5th ed.). St. Louis: Saunders Elsevier.)

**FIGURE 1.2** Well-made peripheral blood film.
(From Keohane E.A., Smith L., Walenga J. (Eds.) (2016). *Rodak's hematology: clinical principles and applications*. (5th ed.). St. Louis: Saunders Elsevier.)



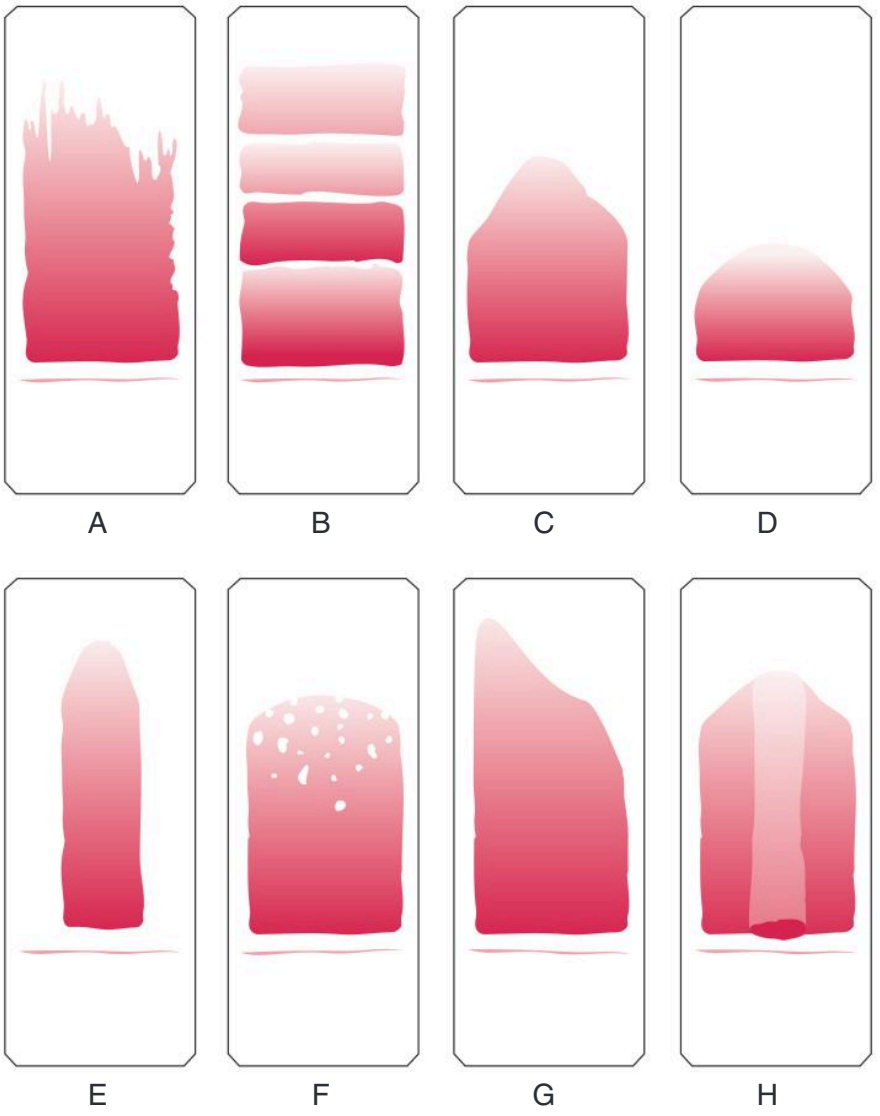


**FIGURE 1.3** Unacceptable peripheral blood films. Slide appearances associated with the most common errors are shown, but note that a combination of causes may be responsible for unacceptable films. (A) Chipped or rough edge on spreader slide. (B) Hesitation in forward motion of spreader slide. (C) Spreader slide pushed too quickly. (D) Drop of blood too small. (E) Drop of blood not allowed to spread across the width of the slide. (F) Dirt or grease on the slide; may also be caused by elevated lipids in the blood specimen. (G) Uneven pressure on the spreader slide. (H) Time delay; drop of blood began to dry.
(From Keohane E.A., Smith L., Walenga J. (Eds.) (2016). *Rodak's hematology: clinical principles and applications*. (5th ed.). St. Louis: Saunders Elsevier.)

## STAINING OF PERIPHERAL BLOOD FILMS

The purpose of staining blood films is to identify cells and recognize morphology easily through the microscope. Wright or Wright-Giemsa stains are the most commonly used for peripheral blood and bone marrow films. These stains contain both eosin and methylene blue and are therefore termed *polychrome stains*. The colors vary slightly from laboratory to laboratory, depending on the method of staining.

Slides must be allowed to dry thoroughly before staining. The cells are fixed to the glass slide by the methanol in the stain. Staining reactions are pH dependent, and the actual staining of the cellular components occurs when a buffer (pH 6.4) is added to the stain. Free methylene blue is basic and stains acidic cellular components, such as RNA, blue. Free eosin is acidic and stains basic components, such as hemoglobin or eosinophilic granules, red. Neutrophils have cytoplasmic granules that have a neutral pH and accept some characteristics from both stains. Details for specific methods of staining peripheral blood and bone marrow films, including automated methods, may be found in a standard textbook of hematology.

An optimally stained film (Figure 1.4) has the following characteristics:

1. The red blood cells (RBCs) should be pink to salmon.
2. Nuclei are dark blue to purple.
3. Cytoplasmic granules of neutrophils are lavender to lilac.
4. Cytoplasmic granules of basophils are dark blue to black.
5. Cytoplasmic granules of eosinophils are red to orange.
6. The area between the cells should be colorless, clean, and free of precipitated stain.

A well-stained slide is necessary for accurate interpretation of cellular morphology. The best staining results are obtained from freshly made slides that have been prepared within 2 to 3 hours of blood collection. Box 1.1 lists common reasons for poorly stained slides and may be used as a guide when troubleshooting.

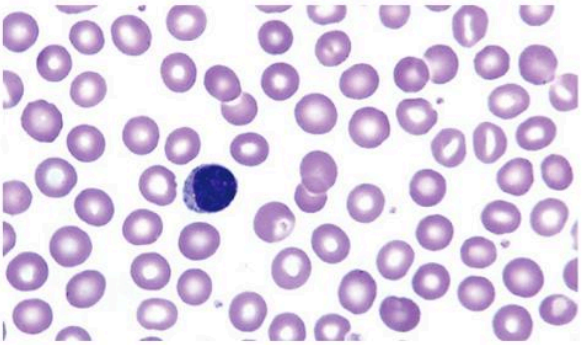

**FIGURE 1.4** Optimally stained peripheral blood film demonstrating the appropriate area in which to perform the white blood cell differential and morphology assessment and the platelet estimate. Only the center of the field is shown; an entire field would contain 200 to 250 red blood cells (original × 1000).

**Box 1.1**

**Troubleshooting Poorly Stained Blood Films**

**First Scenario**

***Problems***

- Red blood cells appear gray
- White blood cells are too dark
- Eosinophil granules are gray, not orange

***Causes***

- Stain or buffer too alkaline (most common)
- Inadequate rinsing
- Prolonged staining
- Heparinized blood sample

**Second Scenario**

***Problems***

- Red blood cells too pale or red color
- White blood cells barely visible

***Causes***

- Stain or buffer too acidic (most common)
- Underbuffering (time too short)
- Over-rinsing

From Keohane E.A., Smith L., Walenga J. (Eds.) (2016). *Rodak's hematology: clinical principles and applications*. (5th ed.). St. Louis: Saunders Elsevier.

## PERIPHERAL FILM EXAMINATION

### 10 × EXAMINATION

Examination of the blood film is a multistep process. Begin the film examination with a scan of the slide using the 10 × or low-power objective (total magnification = 100 ×). This step is necessary to assess the overall quality of the film, including abnormal distribution of RBCs, suggesting the presence of rouleaux or autoagglutination, and/or the presence of a disproportionate number of large nucleated cells such as monocytes or neutrophils at the edges of the film. If the latter exists, another film should be prepared. In addition, the 10 × film examination allows for the rapid detection of large abnormal cells such as blasts, reactive lymphocytes, and parasites.

### 40 × OR 50 × EXAMINATION

Using the 40 × (high dry) objective or the 50 × oil objective (400 × and 500 × total magnification, respectively), find an area of the film in which the RBCs are evenly distributed and barely touching one another (two or three cells may overlap; Figure 1.5). Scan 8 to 10 fields in this area of the film, and determine the average number of white blood cells (WBCs) per field. Although an exact factor varies with the make

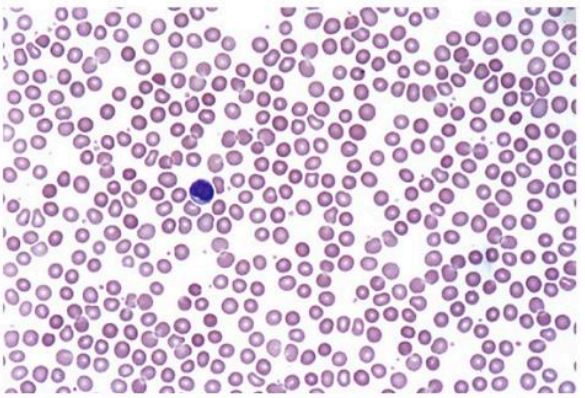

**FIGURE 1.5** Correct area of blood film in which to evaluate cellular distribution and perform white blood cell estimate (× 400).

and model of microscope, in general, an approximate WBC count per cubic millimeter can be determined by multiplying the average number of WBCs per high-power field by 2000 (if 40 × is used), or 2500 (if 50 × is used). This estimate is a useful quality-control tool for validating WBC counts from hematology analyzers. Any discrepancy between the instrument WBC count and the slide estimate must be resolved. Some reasons for discrepancies include the presence of WBC or platelet clumps, fibrin strands, severe RBC agglutination, cryoglobulin and giant platelets, in addition to a mislabeled film, a film made from the wrong patient's sample, and an instrument malfunction.

## 100 × EXAMINATION

The next step in film evaluation is to perform the WBC differential. This is done in the same area of the film as the WBC estimate but using the 100 × oil immersion objective (1000 × total magnification). When the correct area of the film from a patient with a normal RBC count is viewed, about 200 to 250 RBCs per oil immersion field are seen (see Figure 1.4). Characteristically, the differential count includes counting and classifying 100 consecutive WBCs and reporting these classes as percentages. The differential count is performed in a systematic manner using the "battlement" track (Figure 1.6), which minimizes WBC distribution errors. The results are reported as percentages of each type of WBC seen during the count. An example of a WBC differential count is 3% bands, 55% segmented neutrophils, 30% lymphocytes, 6% monocytes, 4% eosinophils, and 2% basophils (Table 1.1). Any WBC abnormalities, such as toxic changes, Döhle bodies, reactive lymphocytes, and Aüer rods, are also reported. When present, nucleated red blood cells (NRBCs) are counted and reported as number of NRBCs per 100 WBCs. The RBC, WBC,

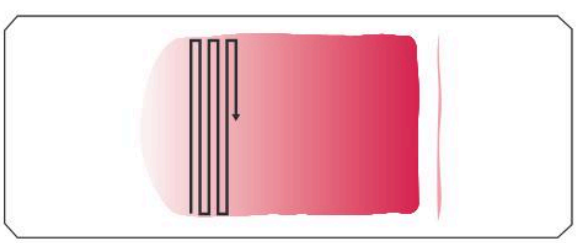

**FIGURE 1.6** "Battlement" pattern for performing a white blood cell differential. (From Keohane E.A., Smith L., Walenga J. (Eds.) (2016). *Rodak's hematology: clinical principles and applications*. (5th ed.). St. Louis: Saunders Elsevier.)

## TABLE 1.1

**Cells Found in a Normal White Blood Cell Differential**

| Cell Type | Cell Size (μm) | Nucleus | Chromatin | Cytoplasm | Granules | Adult Reference Range: Peripheral Blood (%) | Adult Reference Range: Cells × $10^9$/L |
|---|---|---|---|---|---|---|---|
| Segmented neutrophil (Seg), polymorphonuclear neutrophil (Poly, PMN) | 10 to 15 | 2 to 5 lobes connected by thin filaments without visible chromatin | Coarsely clumped | Pale pink, cream colored, or colorless | 1°: Rare<br>2°: Abundant | 50 to 70 | 2.3 to 8.1 |
| Band neutrophil (Band) | 10 to 15 | Constricted, but chromatin must be visible within the thinnest part | Coarsely clumped | Pale blue to pink | 1°: Few<br>2°: Abundant | 0 to 5 | 0.0 to 0.6 |
| Lymphocyte (Lymph) | 7 to 18* | Round to oval; may be slightly indented; occasional nucleoli | Condensed to deeply condensed | Scant to moderate; sky blue | ± Few azurophilic | 20 to 40 | 0.8 to 4.8 |
| Monocyte (Mono) | 12 to 20 | Variable; may be round, horseshoe, or kidney shaped; often has folds producing "brainlike" convolutions | Moderately clumped; lacy | Blue-gray; may have pseudopods; vacuoles may be absent or numerous | Many fine granules, frequently giving the appearance of ground glass | 3 to 11 | 0.5 to 1.3 |
| Eosinophil (Eos) | 12 to 17 | 2 to 3 lobes connected by thin filaments without visible chromatin | Coarsely clumped | Cream to pink; may have irregular borders | 1°: Rare<br>2°: Abundant red to orange, round | 0 to 5 | 0.0 to 0.4 |
| Basophil (Baso) | 10 to 14 | Usually two lobes connected by thin filaments without visible chromatin | Coarsely clumped | Lavender to colorless | 1°: Rare<br>2°: Lavender to dark purple; variable in number with uneven distribution; may obscure nucleus or wash out during staining, giving the appearance of empty areas in cytoplasm | 0 to 1 | 0.0 to 0.1 |

*The difference in size from small to large lymphocyte is primarily a result of a larger amount of cytoplasm. See Chapter 9 for more detailed information on lymphocyte size.

*1°*, Primary; *2°*, secondary.

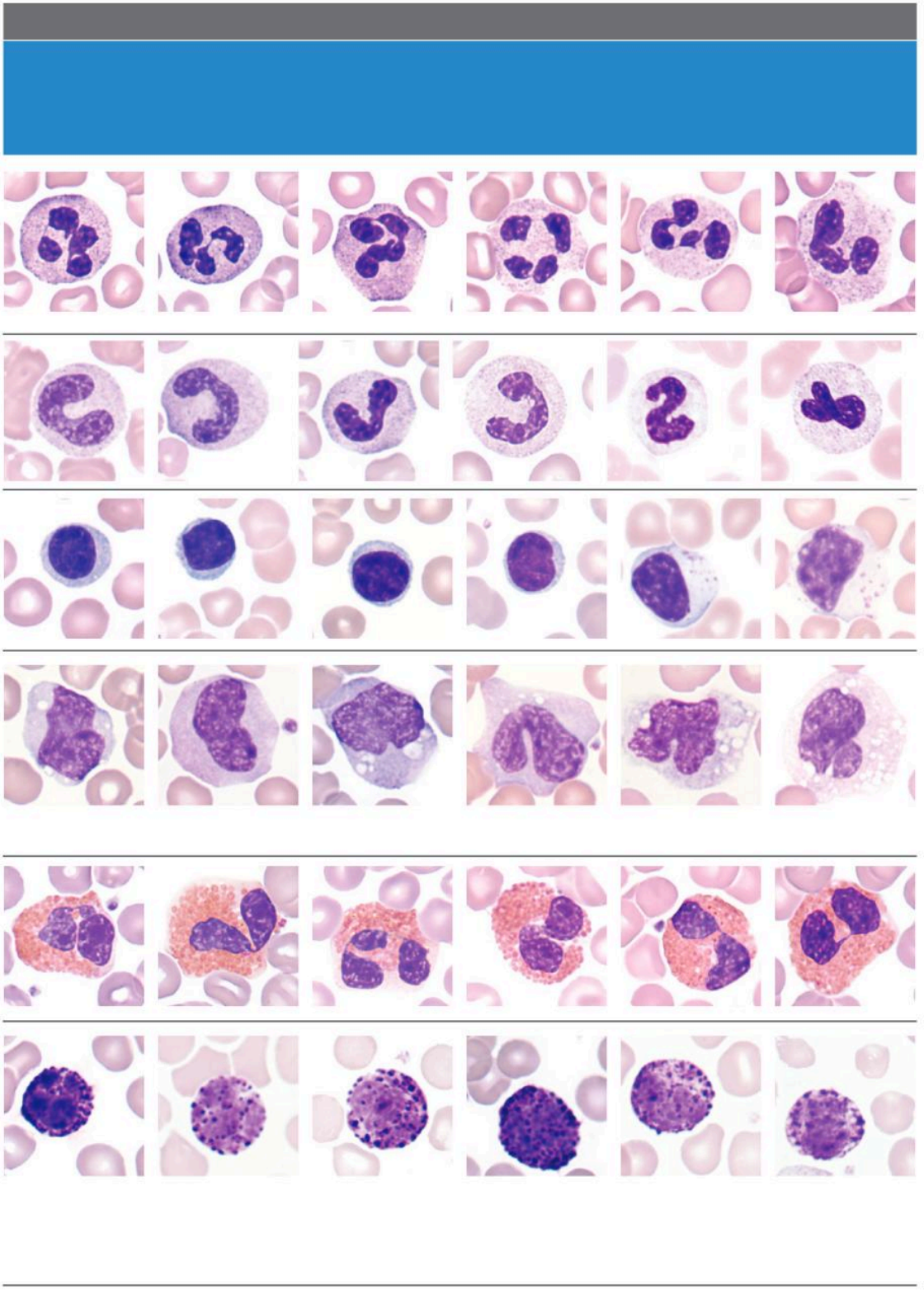

platelet morphology evaluation, and platelet estimates are also performed under the 100 × oil immersion objective. RBC inclusions, such as Howell-Jolly bodies, and WBC inclusions, such as Döhle bodies, can be seen at this magnification. Each laboratory should have established protocols for standardized reporting of abnormalities.

Evaluation of the RBC morphology is an important aspect of the film evaluation and is used in conjunction with the RBC indices to describe cells as normal or abnormal in size, shape, and color. Each laboratory should establish a standard reporting protocol. Most laboratories use concise statements describing overall RBC morphology that is consistent with the RBC indices. The microscopic evaluation of RBC morphology must be congruent with the information given by the automated hematology analyzer. If not, discrepancies must be resolved before reporting patient results.

The final step in the performance of the differential count is the estimation of the platelet number. This is done under the 100 × oil immersion objective. In an area of the film where RBCs barely touch, the number of platelets in 5 to 10 oil immersion fields is counted. The average number of platelets is multiplied by 20,000 to provide an estimate of the total number of platelets per cubic millimeter. This estimate is reported as adequate if the estimate is consistent with a normal platelet count, decreased if below the lower limit of normal for that laboratory, and increased if above the upper limit of normal. A general reference range is 150,000 to 450,000/$mm^3$ (150–450 × $10^9$/L). When a patient is extremely anemic or has erythrocytosis, a more involved formula for platelet estimates may be used.

The estimate can be compared with an automated platelet count as an additional quality-control measure. If the estimate and the instrument platelet count do not agree, discrepancies must be resolved. Some causes for discrepancies include the presence of giant platelets, many schistocytes (RBC fragments), and platelet satellitism. Notably, high-quality 40 × or 50 × oil immersion objectives can be used by the experienced technologist to perform the differential analysis of the blood film. However, all abnormal findings must be verified under the 100 × objective.

## SUMMARY

A considerable amount of valuable information can be obtained from properly prepared, stained, and evaluated peripheral blood films. Many laboratories use films made by the wedge technique from EDTA anticoagulated blood and stained with Wright or Wright-Giemsa stain. The films should be evaluated in a systematic manner using first the 10 ×, then 40 × high dry or 50 × oil, and finally the 100 × oil immersion objectives on the microscope. WBC differential and morphology and the RBC morphology and platelet estimate are included in the film evaluation.

CHAPTER 2

# HEMATOPOIESIS

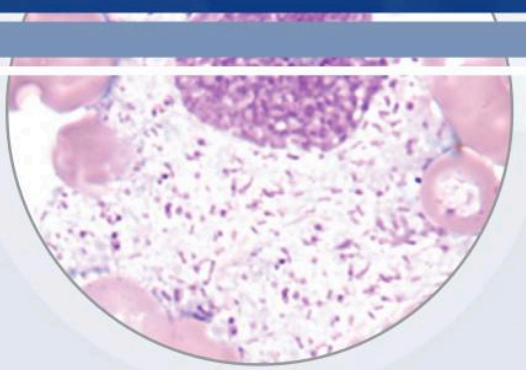

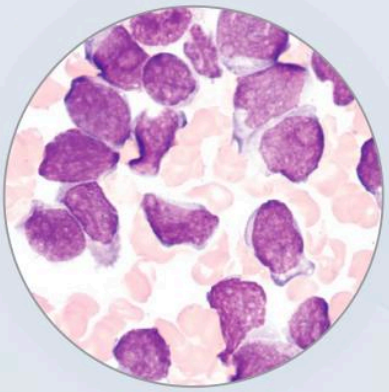

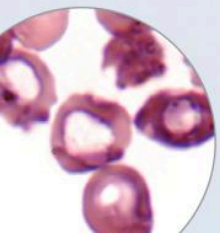

Hematopoiesis is a vigorous process of blood cell production and maturation that occurs primarily in the bone marrow in the adult. The process begins with the pluripotential hematopoietic stem cell (multipotent progenitor), which is capable of proliferation, replication, and differentiation. In response to cytokines (growth factors), the pluripotential stem cell will differentiate into a common myeloid or common lymphoid progenitor. Both the myeloid and lymphoid progenitors maintain their pluripotential capacity. The lymphoid progenitor proliferates and differentiates into T, B, and natural killer cells. The myeloid progenitor proliferates and differentiates into granulocyte, monocyte, erythrocyte, and megakaryocyte lineages. To this point in maturation, none of these stem cells can be morphologically identified, although it is postulated that they appear similar to a small resting lymphocyte. The light blue shaded area in Figure 2.1 highlights the stem cell populations. Each lineage and maturation stage will be presented in detail in the following chapters.

Hematopoiesis is a dynamic continuum. Cells gradually mature from one stage to the next and may be between stages when viewed through the microscope. In general, the cell is then identified as the more mature stage. General morphological changes in blood cell maturation are demonstrated in Figure 2.2.

Figure 2.3A–B illustrate cell ultrastructure. A review of organelles will facilitate correlation of morphological maturation with cell function. This topic is explored in depth in hematology textbooks, such as *Rodak's Hematology: Clinical Principles and Applications*, sixth edition. Table 2.1 delineates the location, appearance, and function of individual organelles.

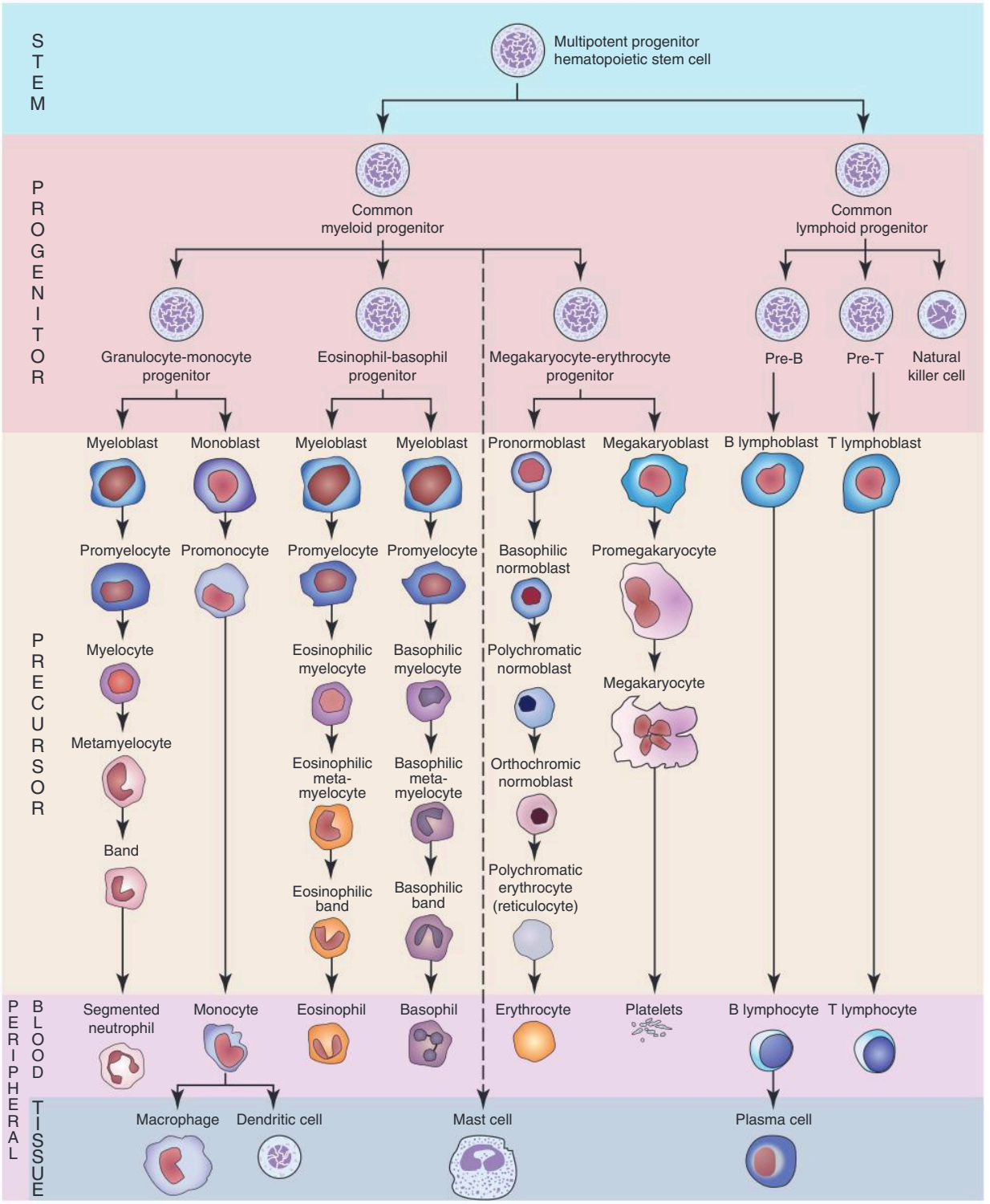


**FIGURE 2.1** Chart of hematopoiesis.

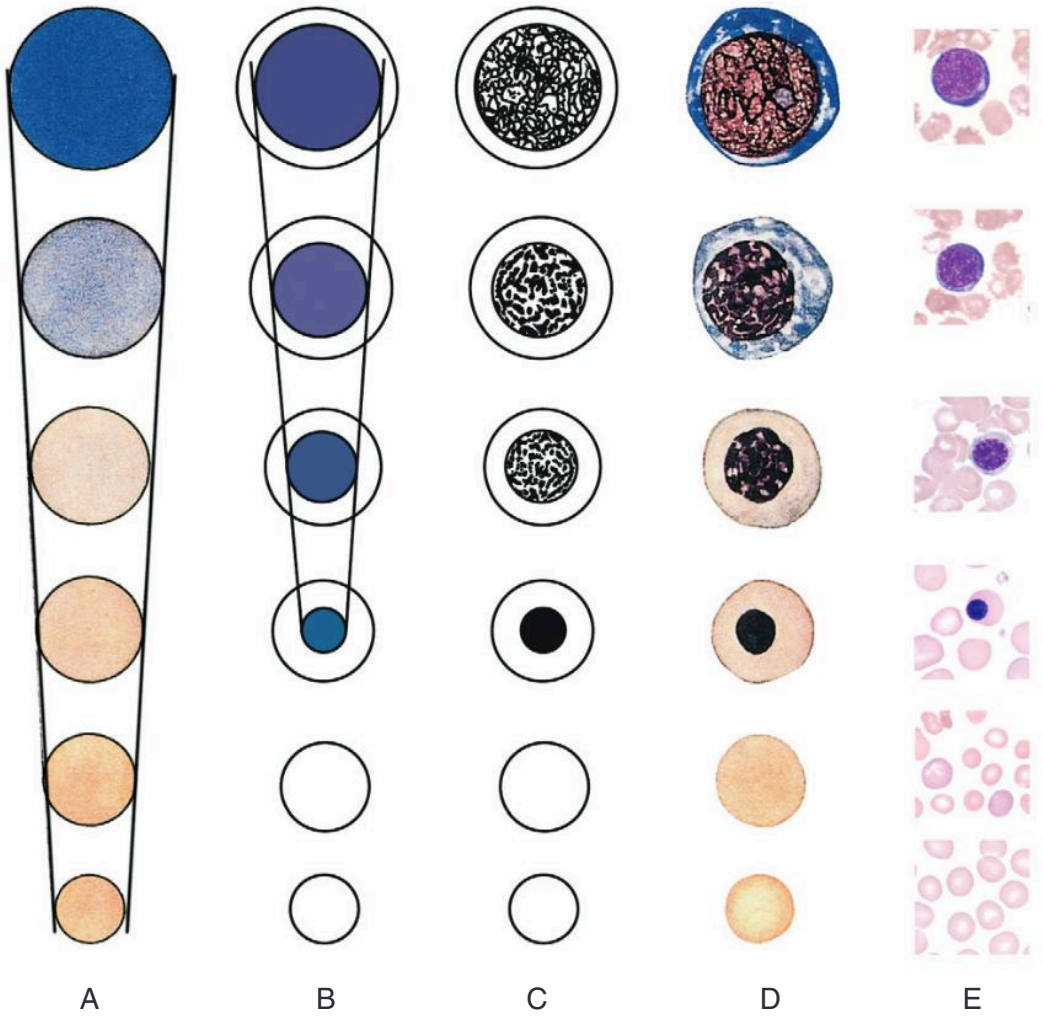


**FIGURE 2.2** General trends that affect the morphology of blood cells during the developmental process.

(A) Cell diameter decreases and cytoplasm becomes less basophilic.
- An exception to the diameter decreasing is observed in the granulocytic series, the promyelocyte may be larger than its precursor, the myeloblast (see Chapter 5, Neutrophil Maturation).
- In the erythroid series, hemoglobin development in the cytoplasm imparts a pink/salmon color.

(B) Nuclear diameter decreases (N:C ratio decreases). Nuclear color changes from purplish red to dark blue.

(C) Nuclear chromatin becomes coarser, clumped, and condensed.
- Nucleoli disappear.
- In the granulocytic series, the nuclear shape changes and the nucleus becomes segmented. Granules appear in cytoplasm (see Chapter 5, Neutrophil Maturation).
- In the erythroid series, the nucleus becomes fully condensed and is ejected.

(D) Composite of changes during maturation process.

(E) Representative cells from the erythroid series, demonstrating maturation changes.

(Modified from Diggs, L.W., Sturm, D., Bell, A. (1985). *The morphology of human blood cells*. (5th ed.). Abbott Park: Abbott Laboratories. Reproduction of *The Morphology of Human Blood Cells* has been granted with approval of Abbott Laboratories, all rights reserved by Abbott Laboratories.)

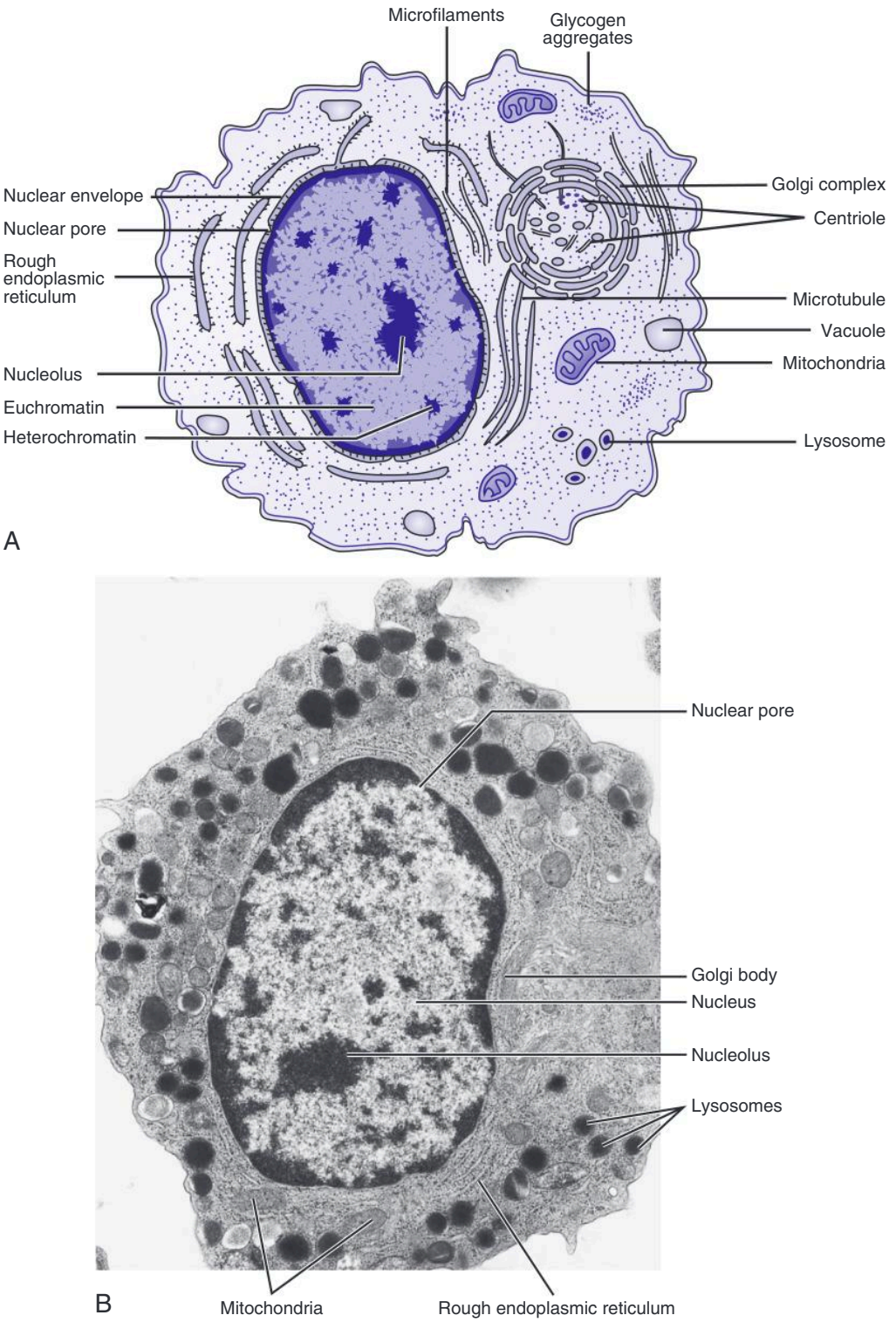


**FIGURE 2.3** (A) Schematic of electron micrograph. (B) Electron micrograph with labeled organelles. ([A] From Keohane E.A., Smith L., Walenga J. (Eds.) (2016). *Rodak's hematology: clinical principles and applications.* (5th ed.). St. Louis: Saunders Elsevier.)

**TABLE 2.1**

**Summary of Cellular Components and Functions**

| Organelle | Location | Appearance and Size | Function | Comments |
|---|---|---|---|---|
| Membranes: plasma, nuclear, mitochondrial, and endoplasmic reticulum | Outer boundary of cell, nucleus, endoplasmic reticulum, mitochondria, and other organelles | Usually a lipid bilayer consisting of proteins, cholesterol, phospholipids, and polysaccharides; membrane thickness varies with cell or organelle | Separates various cellular components; facilitates and restricts cellular exchange of substances | Membrane must be resilient and flexible |
| Nucleus | Within cell | Usually round or oval but varies depending on cell; varies in size; composed of DNA | Control center of cell containing the genetic blueprint | Governs cellular activity and transmits information for cellular control |
| Nucleolus | Within nucleus | Usually round or irregular in shape; 2 to 4 μm in size; composed of RNA; there may be 1 to 4 within nucleus | Site of synthesis and processing of ribosomal RNA | Appearance varies with activity of the cells; larger when cell is actively involved in protein synthesis |
| Golgi body | Next to nucleus | System of stacked, membrane-bound, flattened sacs; horseshoe shaped; varies in size | Involved in modifying and packaging macromolecules for secretion | Well developed in cells with large secretion responsibilities |
| Endoplasmic reticulum | Randomly distributed throughout cytoplasm | Membrane-lined tubules that branch and connect to nucleus and plasma membrane | Stores and transports fluids and chemicals | Two types: smooth with no ribosomes, rough with ribosomes on the surface |
| Ribosomes | Free in cytoplasm; outer surface of rough endoplasmic reticulum | Small granule, 100 to 300 Å; composed of protein and nucleic acid | Site of production of proteins, such as enzymes and blood proteins | Large proteins are synthesized from polyribosomes (chains of ribosomes) |
| Mitochondria | Randomly distributed in cytoplasm | Round or oval structures; 3 to 14 nm in length; 2 to 10 nm in width; membrane has two layers; inner layer has folds called *cristae* | Cell's "powerhouse"; make ATP, the energy source for the cell | Active cells have more present than do inactive ones |
| Lysosomes | Randomly distributed in cytoplasm | Membrane-bound sacs; size varies | Contain hydrolytic enzymes for cellular digestive system | If the membrane breaks, hydrolytic enzymes can destroy the cell |
| Microfilaments | Near nuclear envelope and within proximity of mitotic process | Small, solid structure approximately 5 nm in diameter | Support cytoskeleton and motility | Consist of actin and myosin (contractile proteins) |
| Microtubules | Cytoskeleton, near nuclear envelope and component part of centriole near Golgi body | Hollow cylinder with protofilaments surrounding the outside tube; 20 to 25 nm in diameter, variable length | Maintains cell shape, motility, and mitotic process | Produced from tubulin polymerization; make up mitotic spindles and part of structure of centriole |
| Centriole | In centrosome near nucleus | Cylinders; 150 nm in diameter, 300 to 500 nm in length | Serves as insertion point for mitotic spindle fibers | Composed of nine sets of triplet microtubules |

(From Keohane E.A., Smith L., Walenga J. (Eds.) (2016). *Rodak's hematology: clinical principles and applications*. (5th ed.). St. Louis: Saunders Elsevier.)
*ATP*, Adenosine triphosphate; *DNA*, deoxyribonucleic acid; *RNA*, Ribonucleic acid.

CHAPTER 3

# ERYTHROCYTE MATURATION

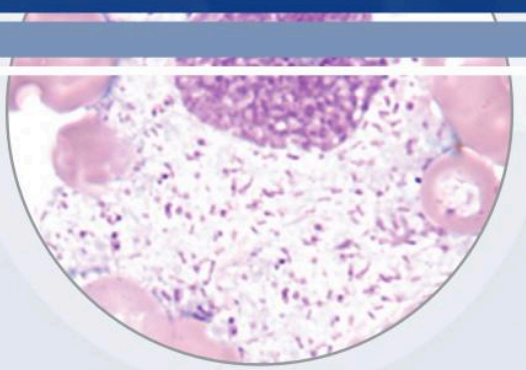

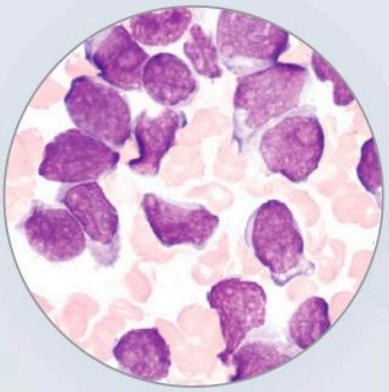

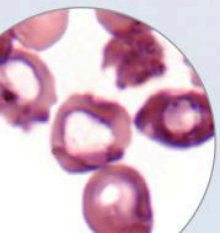

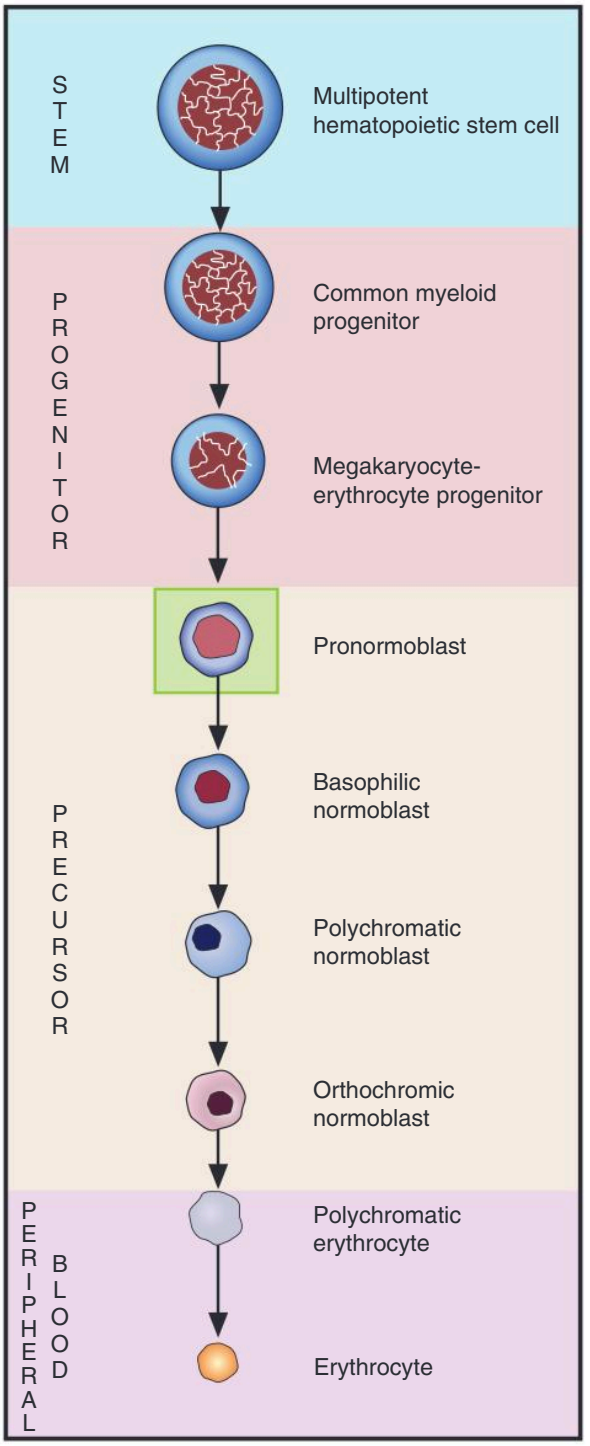


**FIGURE 3.1** Erythrocyte sequence: pronormoblast.

All photomicrographs are ×1000 original magnification with Wright-Giemsa staining unless stated otherwise.

## PRONORMOBLAST

**Proerythroblast**
**Rubriblast**

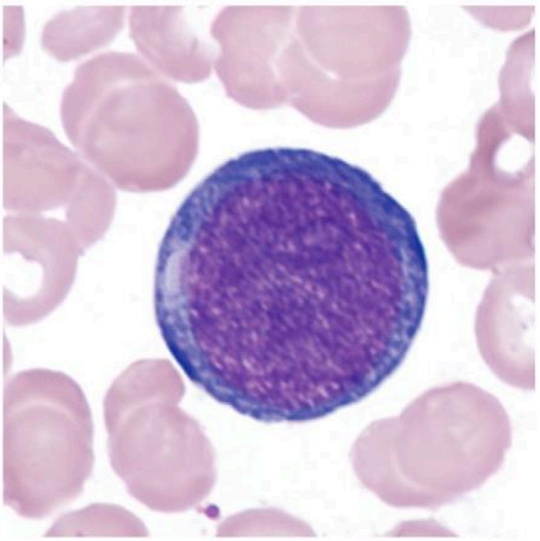

A

**FIGURE 3.2A** Pronormoblast.

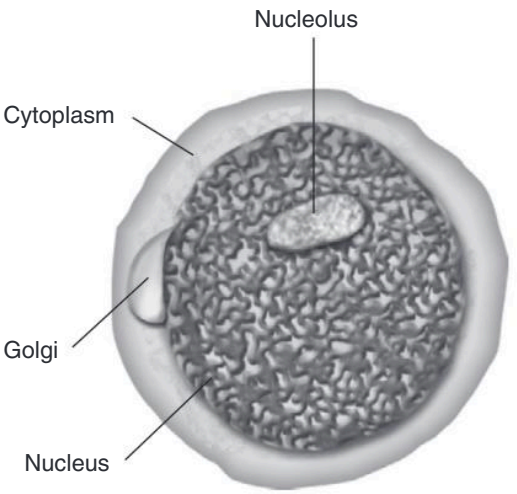


B

**FIGURE 3.2B** Schematic of pronormoblast.

**SIZE:** 12 to 20 µm

**NUCLEUS**: Round to slightly oval
**Nucleoli:** 1 to 2
**Chromatin:** Fine

**CYTOPLASM:** Dark blue; may have prominent Golgi

**N:C RATIO:** 8:1

**REFERENCE INTERVAL:**
**Bone Marrow:** 1%
**Peripheral Blood:** 0%

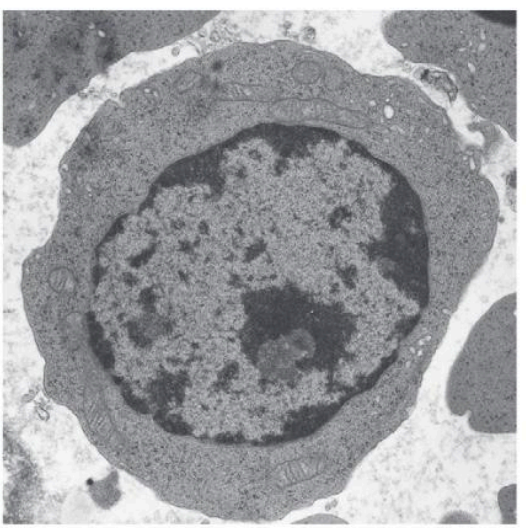

C

**FIGURE 3.2C** Electron micrograph of pronormoblast (×15,575).

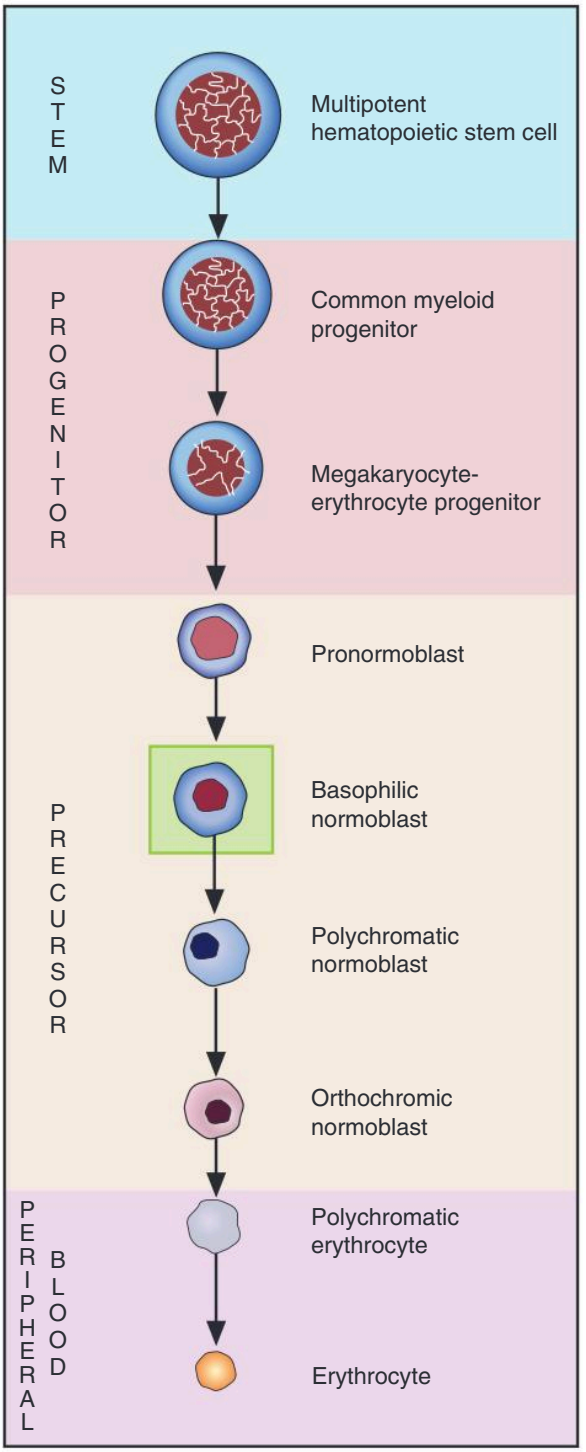


**FIGURE 3.3** Erythrocyte sequence: basophilic normoblast.

## BASOPHILIC NORMOBLAST

**Basophilic Erythroblast**

**Prorubricyte**

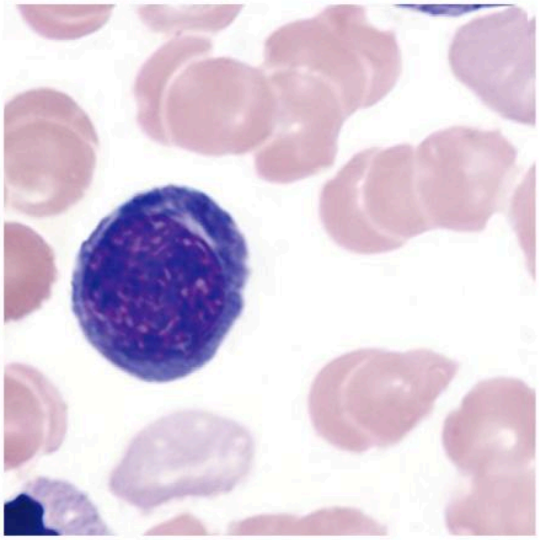

A

**FIGURE 3.4A** Basophilic normoblast.

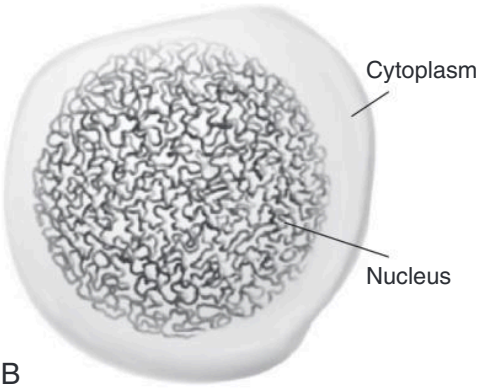


B

**FIGURE 3.4B** Schematic of basophilic normoblast.

**SIZE:** 10 to 15 μm

**NUCLEUS:** Round to slightly oval
**Nucleoli:** 0 to 1
**Chromatin:** Slightly condensed

**CYTOPLASM:** Dark blue

**N:C RATIO:** 6:1

**REFERENCE INTERVAL:**
**Bone Marrow:** 1% to 4%
**Peripheral Blood:** 0%

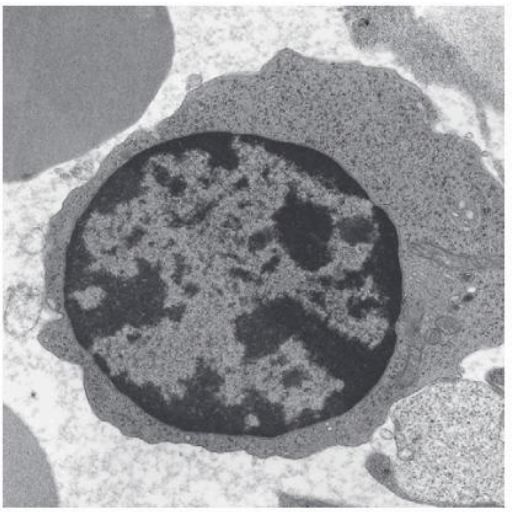

C

**FIGURE 3.4C** Electron micrograph of basophilic normoblast (×15,575).

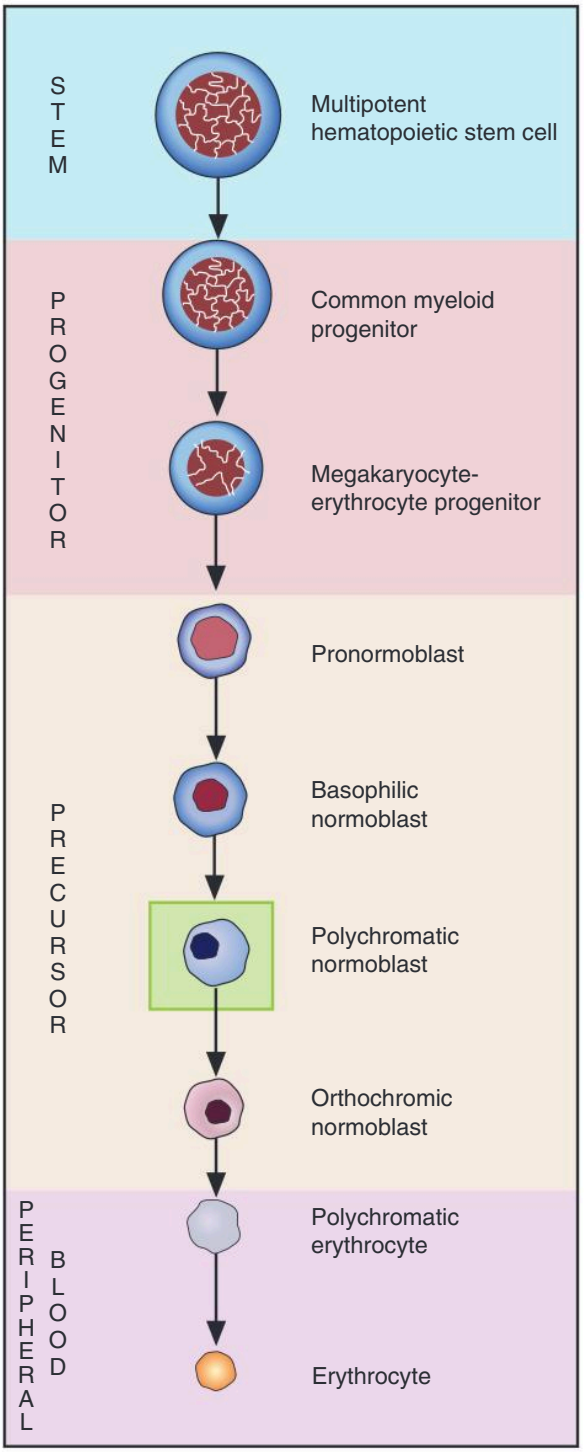


**FIGURE 3.5** Erythrocyte sequence: polychromatic normoblast.

## POLYCHROMATIC NORMOBLAST

### Polychromatic Erythroblast

### Rubricyte

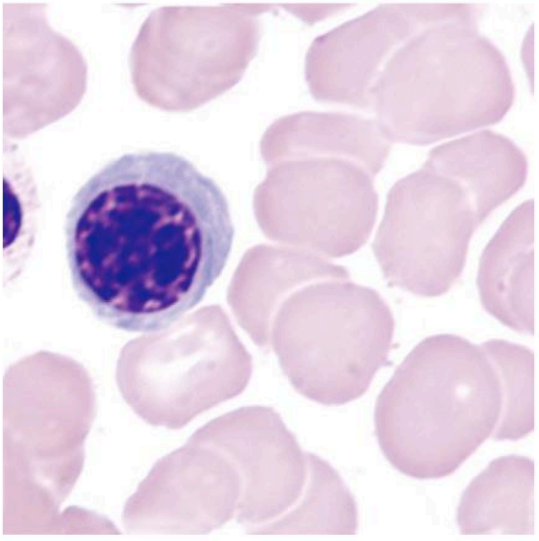

A

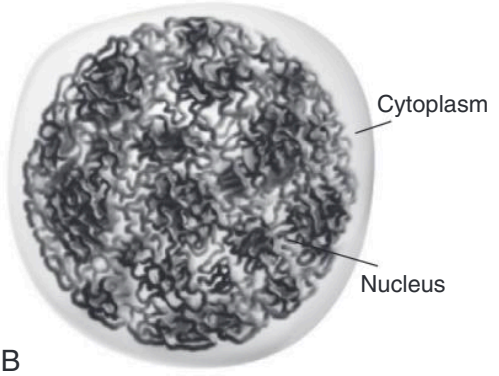


B

**FIGURE 3.6A** Polychromatic normoblast. The blue color of the cytoplasm is becoming gray-blue as hemoglobin is produced.

**FIGURE 3.6B** Schematic of polychromatic normoblast.

**SIZE:** 10 to 12 µm

**NUCLEUS:** Round
**Nucleoli:** None
**Chromatin:** Quite condensed

**CYTOPLASM:** Gray-blue as a result of hemoglobinization

**N:C RATIO:** 4:1

**REFERENCE INTERVAL:**
**Bone Marrow:** 10% to 20%
**Peripheral Blood:** 0%

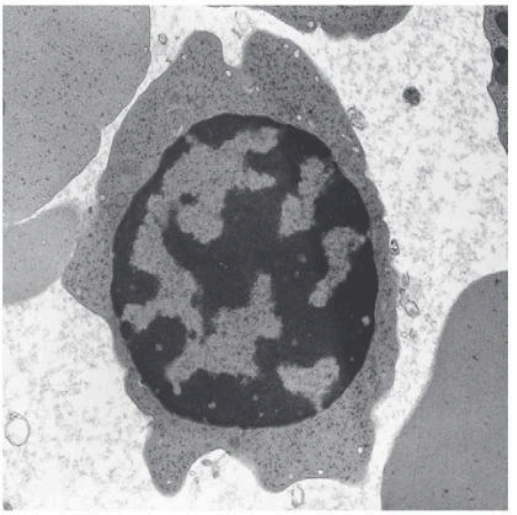

C

**FIGURE 3.6C** Electron micrograph of polychromatic normoblast (×15,575).

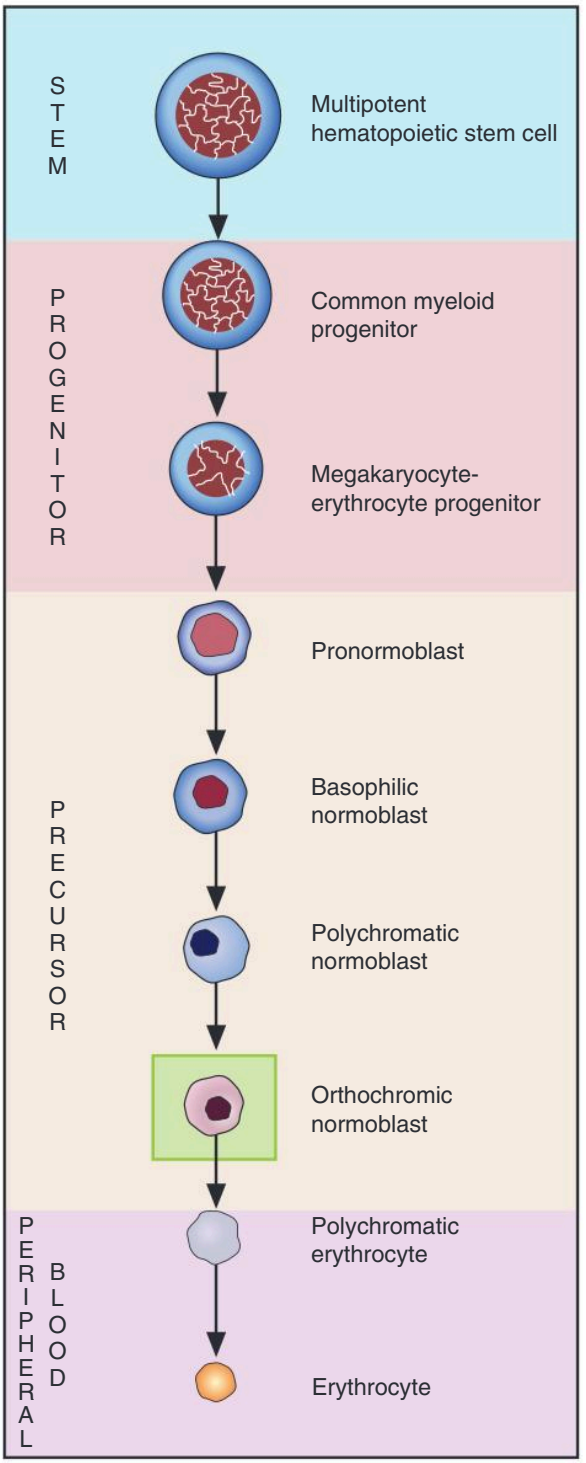


**FIGURE 3.7** Erythrocyte sequence: orthochromic normoblast.

## ORTHOCHROMIC NORMOBLAST

### Orthochromic Erythroblast

### Metarubricyte

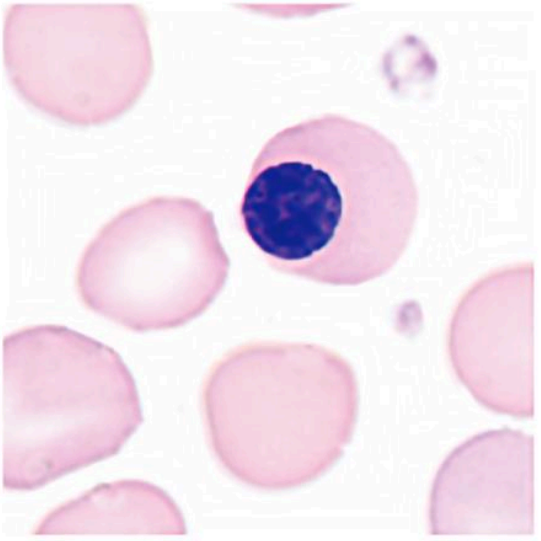

A

**FIGURE 3.8A** Orthochromic normoblast. The gray-blue color of the cytoplasm is becoming salmon as more hemoglobin is produced.

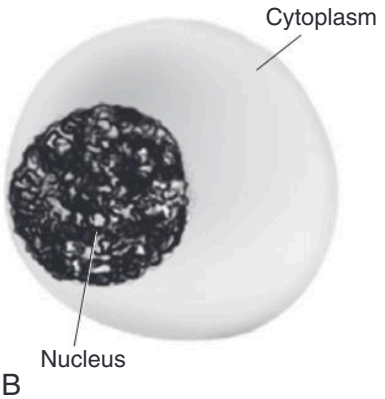


B

**FIGURE 3.8B** Schematic of orthochromic normoblast.

**SIZE:** 8 to 10 μm

**NUCLEUS:** Round
**Nucleoli:** 0
**Chromatin:** Fully condensed

**CYTOPLASM:** More pink or salmon than blue

**N:C RATIO:** 0.5:1

**REFERENCE INTERVAL:**
**Bone Marrow:** 5% to 10%
**Peripheral Blood:** 0%

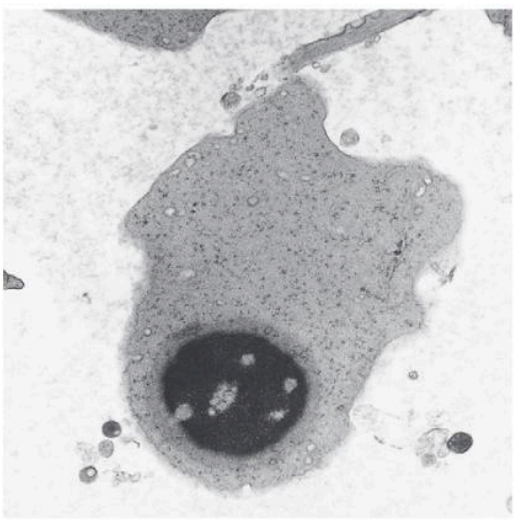

C

**FIGURE 3.8C** Electron micrograph of orthochromic normoblast (×20,125).

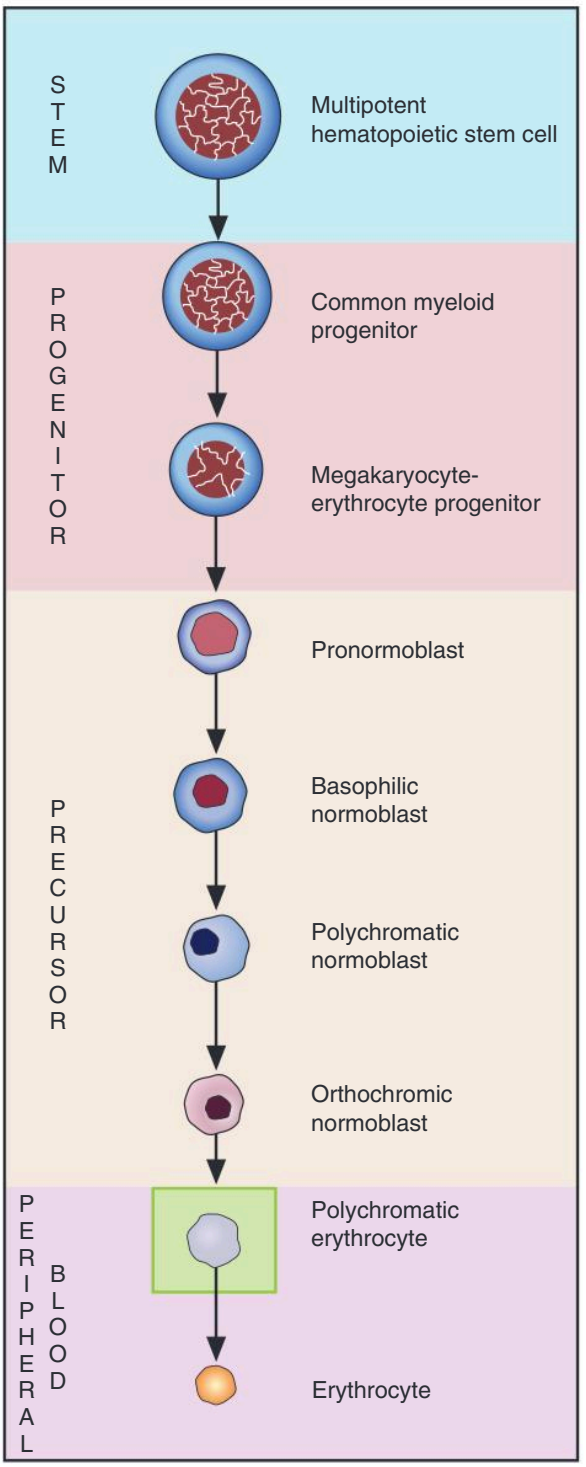


**FIGURE 3.9** Erythrocyte sequence: polychromatic erythrocyte (reticulocyte).

## POLYCHROMATIC ERYTHROCYTE

### Diffusely Basophilic Erythrocyte
### Reticulocyte

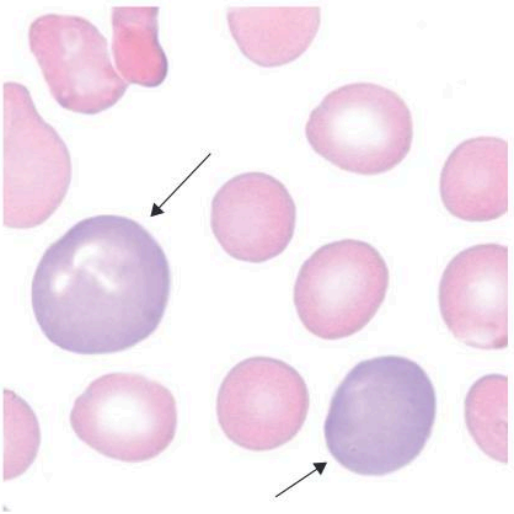

A

**FIGURE 3.10A** Polychromatic erythrocyte. Sometimes appears "lumpy" and larger than mature red blood cells. Slight gray-blue color persists (*arrows*) while the cell attains full hemoglobinization.



B

**FIGURE 3.10B** Scanning electron micrograph of polychromatic erythrocyte (×5000). Note that the reticulocyte is a very deformable cell, giving it a "lumpy" appearance by scanning electron microscopy.

**SIZE:** 8 to 8.5 μm

**NUCLEUS:** Absent
**Nucleoli:** NA
**Chromatin** NA

**CYTOPLASM:** Color is slightly more blue/purple than the mature erythrocyte

**N:C RATIO:** NA

**REFERENCE INTERVAL:**
**Bone Marrow:** 1%
**Peripheral Blood:** 0.5% to 2.0%

**NOTE:** When stained with supravital stain (e.g., new methylene blue), polychromatic erythrocytes appear as reticulocytes (contain precipitated ribosomal material; see Figure 12.5A).

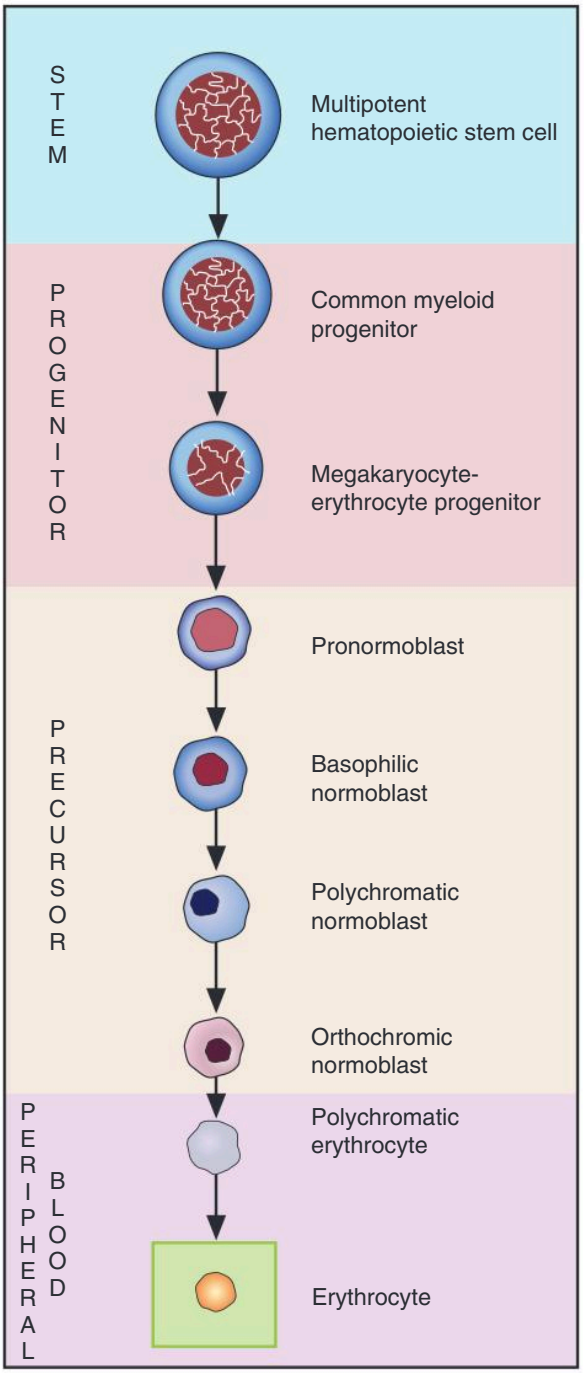


**FIGURE 3.11** Erythrocyte sequence: erythrocyte.

## ERYTHROCYTE



A

**FIGURE 3.12A** Erythrocyte. The mature erythrocyte has lost the blue-gray color and is salmon colored as hemoglobinization is complete.

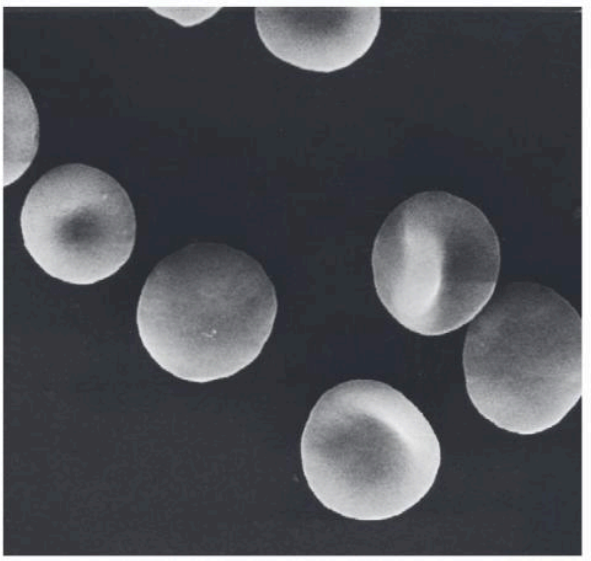

B

**FIGURE 3.12B** Scanning electron micrograph of erythrocyte (×2500).

**SIZE:** 7 to 8 μm

**NUCLEUS:** Absent
**Nucleoli:** NA
**Chromatin:** NA

**CYTOPLASM:** Salmon with central pallor of about one-third of the diameter of the cell

**N:C RATIO:** NA

**REFERENCE INTERVAL**
**Bone Marrow:** NA
**Peripheral Blood** :Predominant cell type

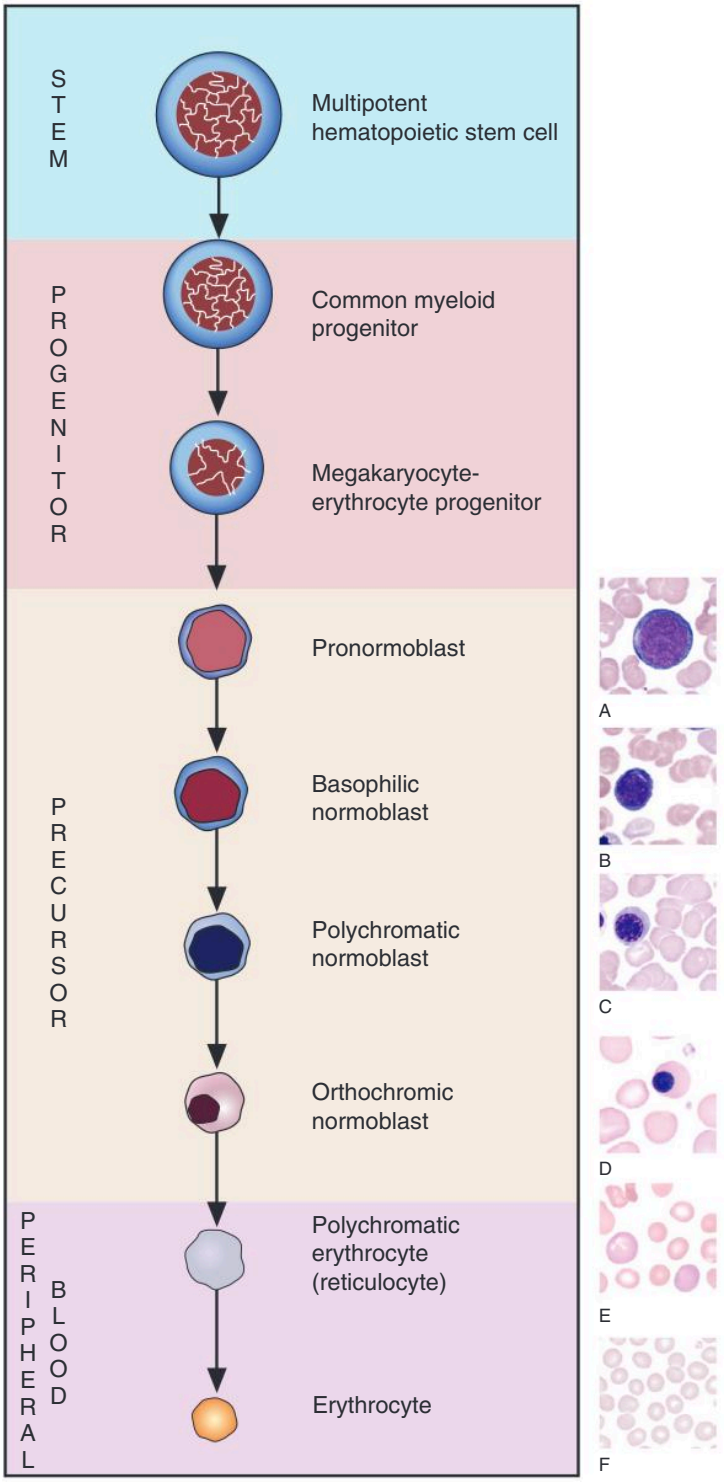


**FIGURE 3.13** Erythrocyte sequence with: (A) pronormoblast; (B) basophilic normoblast; (C) polychromatic normoblast; (D) orthochromic normoblast; (E) polychromatic erythrocyte; and (F) erythrocyte.

CHAPTER 4

# MEGAKARYOCYTE MATURATION

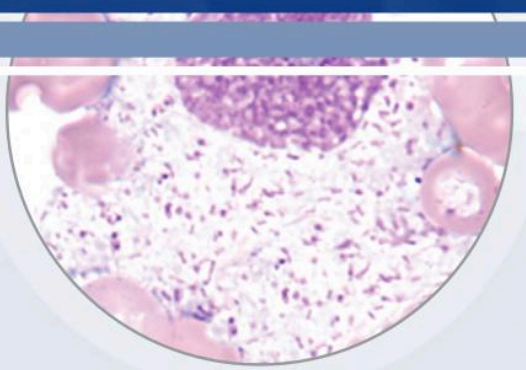

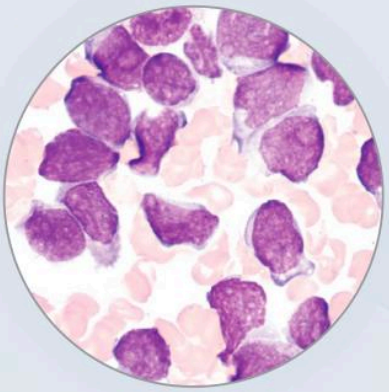

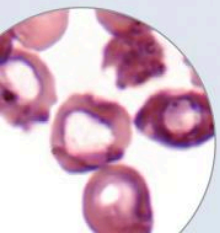

Platelets arise from the megakaryocyte. Megakaryocytes are among the largest cells in the body and mature by a unique process called *endomitosis*. In endomitosis, the nucleus is duplicated but there is no cell division, resulting in a polyploid cell. Megakaryocyte nuclei may have from 2 to 32 lobes and in unusual cases may have up to 64 lobes. Megakaryocytes develop copious cytoplasm, which differentiates into platelets. Platelets have several types of granules that can be visualized by electron microscopy. The granules are highly specialized. Refer to a hematology textbook, such as *Rodak's Hematology: Clinical Principles and Applications*, sixth edition, for further discussion.

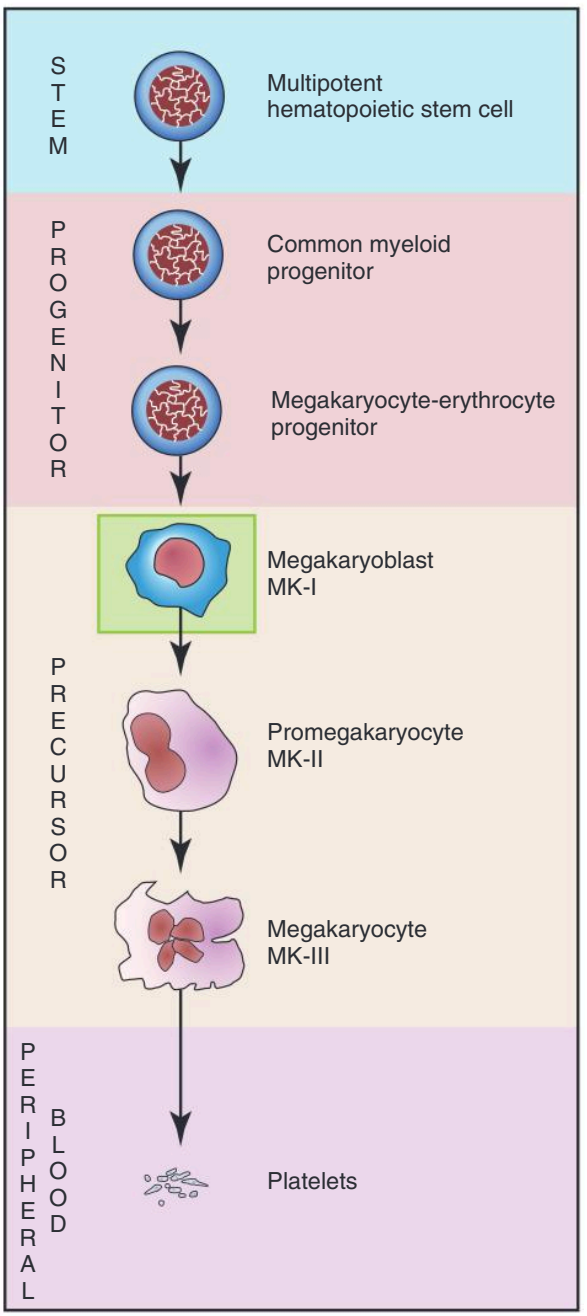


**FIGURE 4.1** Megakaryocyte sequence: megakaryoblast (MK-I).

## MEGAKARYOBLAST (MK-I)

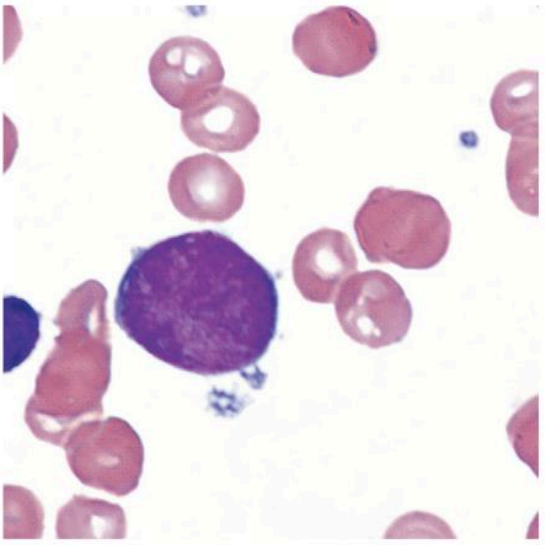

A

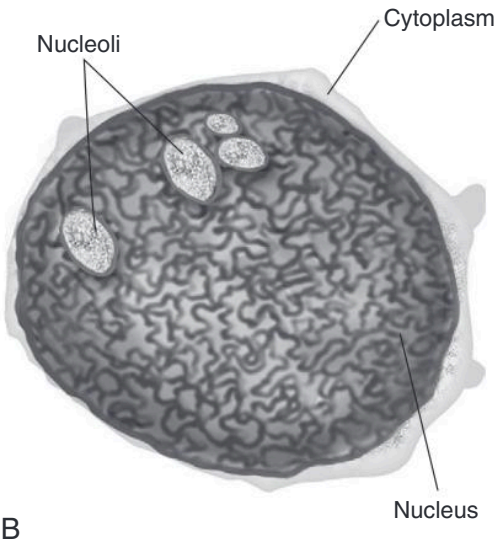


B

**FIGURE 4.2A** Megakaryoblast (MK-I): bone marrow (×1000).

**FIGURE 4.2B** Megakaryoblast, schematic.

**SIZE:** 10 to 24 μm

**NUCLEUS:** Round
**Nucleoli:** 2 to 6
**Chromatin:** Homogeneous, loosely organized

**CYTOPLASM:** Basophilic
**Granules:** Absent by Wright stain

**N:C RATIO:** 3:1

**REFERENCE INTERVAL:**
**Bone Marrow:** 20% of megakaryocyte precursors in bone marrow
**Peripheral Blood:** 0%

**NOTE:** The megakaryoblast appears similar to the myeloblast and pronormoblast. Identification by morphology alone is not advisable.

All photomicrographs are ×1000 original magnification with Wright-Giemsa staining unless stated otherwise.

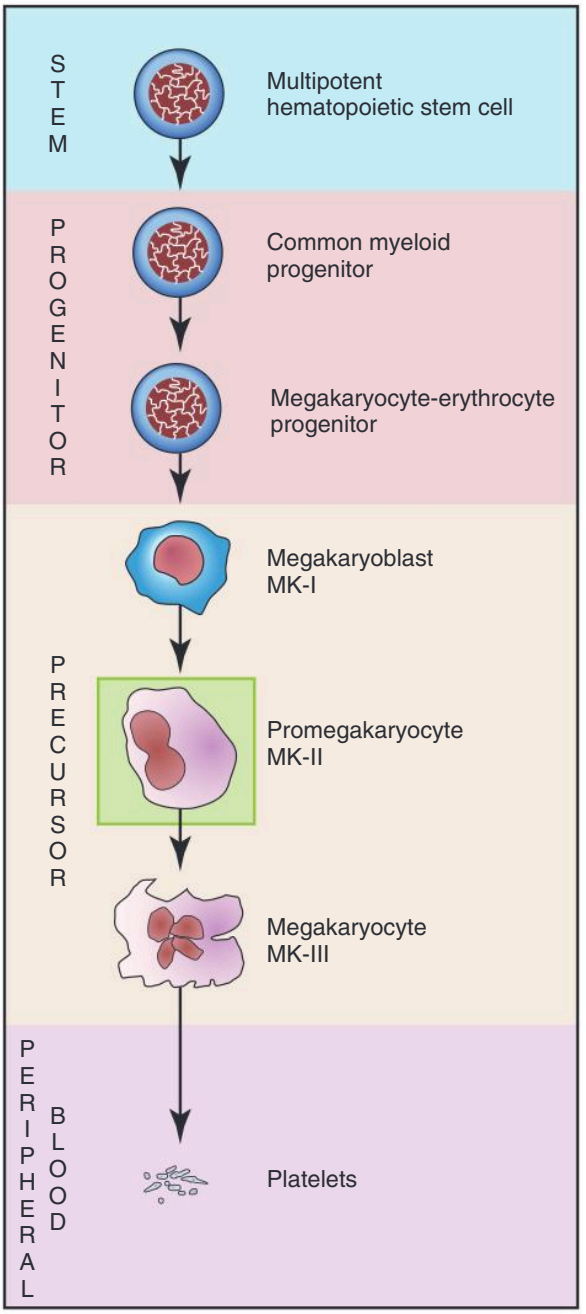


**FIGURE 4.3** Megakaryocyte sequence: promegakaryocyte (MK-II).

## PROMEGAKARYOCYTE (MK-II)

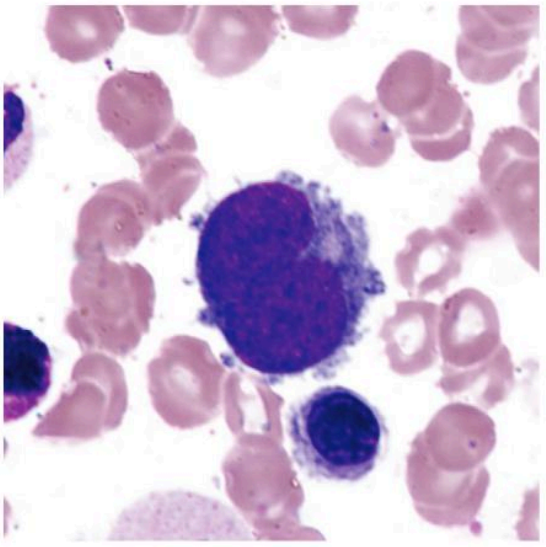

A

**FIGURE 4.4A** Promegakaryocyte (MK-II): bone marrow (×1000).

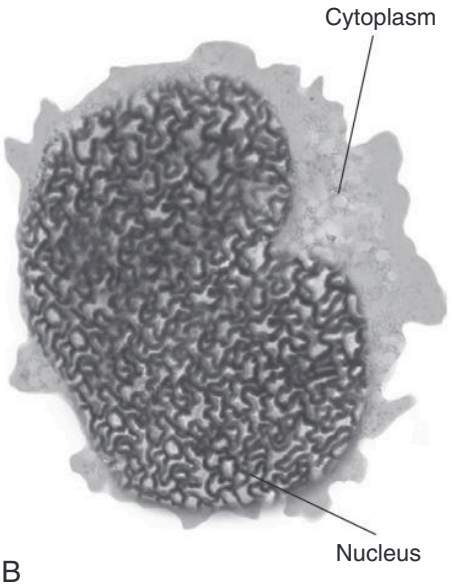


B

**FIGURE 4.4B** Promegakaryocyte, schematic.

**SIZE:** 15 to 40 μm

**NUCLEUS:** Indented
**Nucleoli:** Variable
**Chromatin:** Condensed

**CYTOPLASM**: Basophilic
**Granules:** Present

**N:C RATIO:** 1:2

**REFERENCE INTERVAL:**
**Bone Marrow:** 25% of megakaryocyte precursors in bone marrow
**Peripheral Blood:** 0%

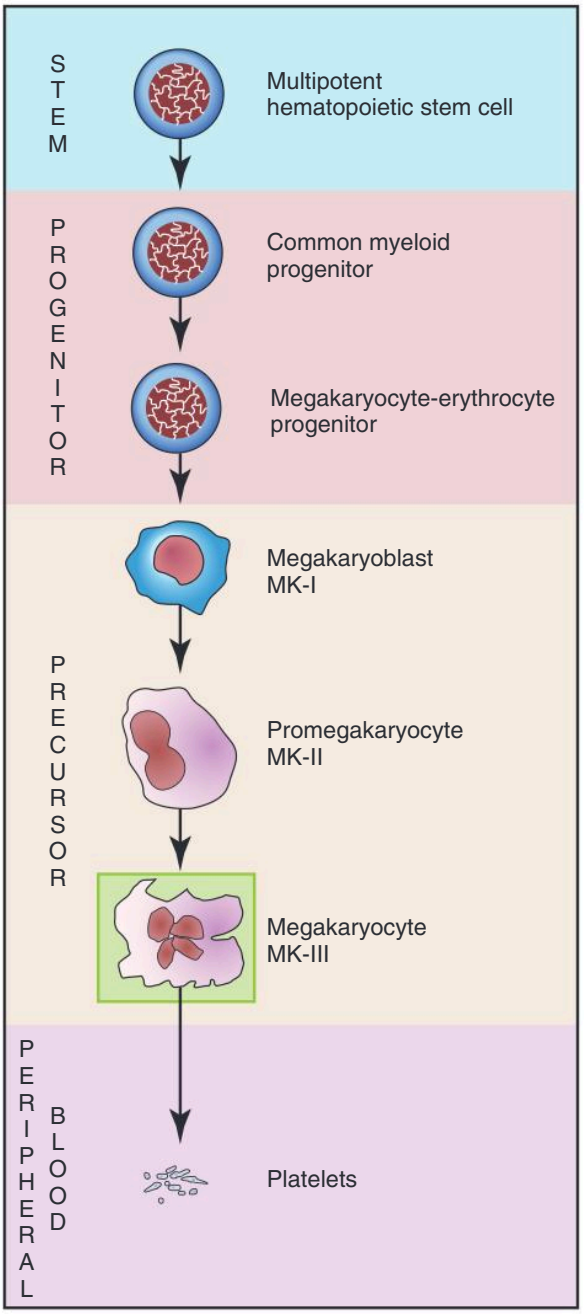


**FIGURE 4.5** Megakaryocyte sequence: megakaryocyte (MK-III).

## MEGAKARYOCYTE (MK-III)

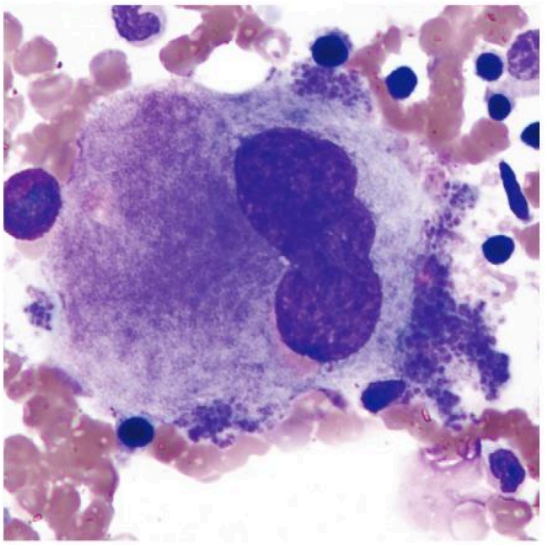

A

**FIGURE 4.6A** Megakaryocyte (MK-III): bone marrow (×500).

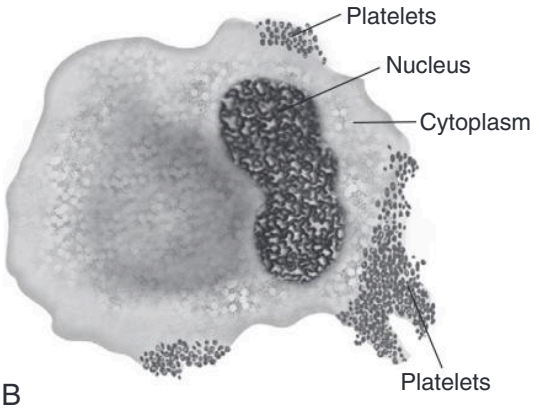


B

**FIGURE 4.6B** Megakaryocyte (MK-III) schematic.

**SIZE:** 20 to 90 μm

**NUCLEUS:** 2 to 32 lobes (8 lobes: most common)

**NOTE:** The size of the cell varies according to the number of lobes present.

**CYTOPLASM:** Blue to pink; abundant
**Granules:** Reddish blue; few to abundant

**N:C RATIO:** Variable

**REFERENCE INTERVAL:**
**Bone Marrow:** 5 to 10 per 10 × objective (×100 magnification)
1 to 2 per 50 × objective (×500 magnification)

**NOTE:** Megakaryocytes are usually reported as adequate, increased, or decreased and not as a percentage.

**Peripheral Blood:** 0%

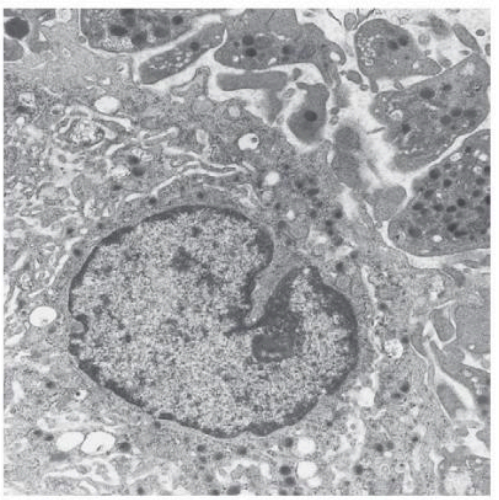

C

**FIGURE 4.6C** Electron micrograph of megakaryocyte (×16,500).

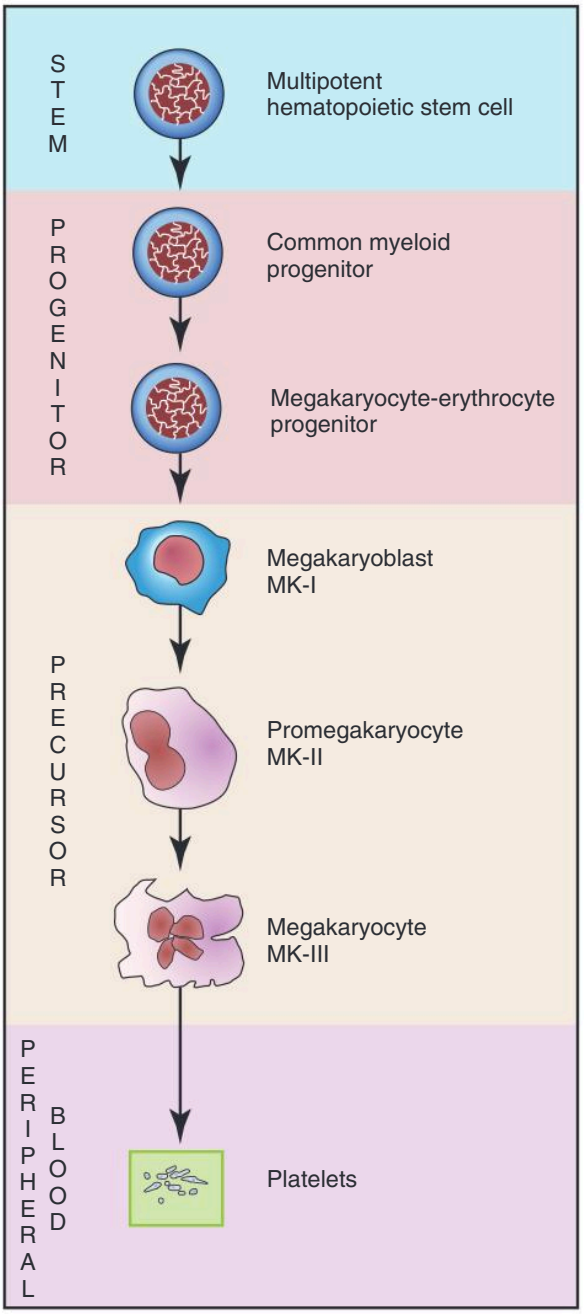


**FIGURE 4.7** Megakaryocyte sequence: platelets.

## PLATELET

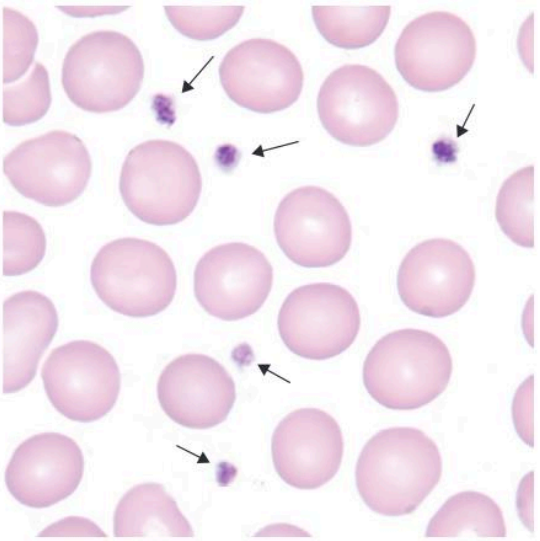

A

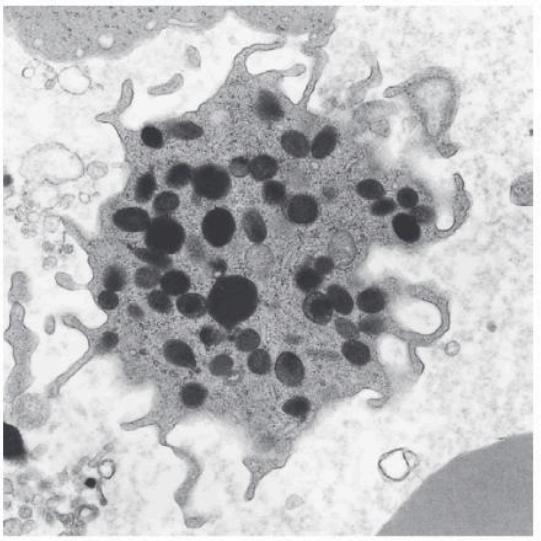

B

**FIGURE 4.8A** Platelet (*arrow*): peripheral blood (×1000).

**FIGURE 4.8B** Electron micrograph of platelet (×28,750).

**SIZE:** 2 to 4 μm

**NUCLEUS:** NA

**CYTOPLASM:** Light blue to colorless
**Granules:** Red to violet; abundant

**N:C RATIO:** NA

**REFERENCE INTERVAL:**
**Bone Marrow:** NA
**Peripheral Blood:** 7 to 25 per 100 × oil immersion field (×1000 magnification)

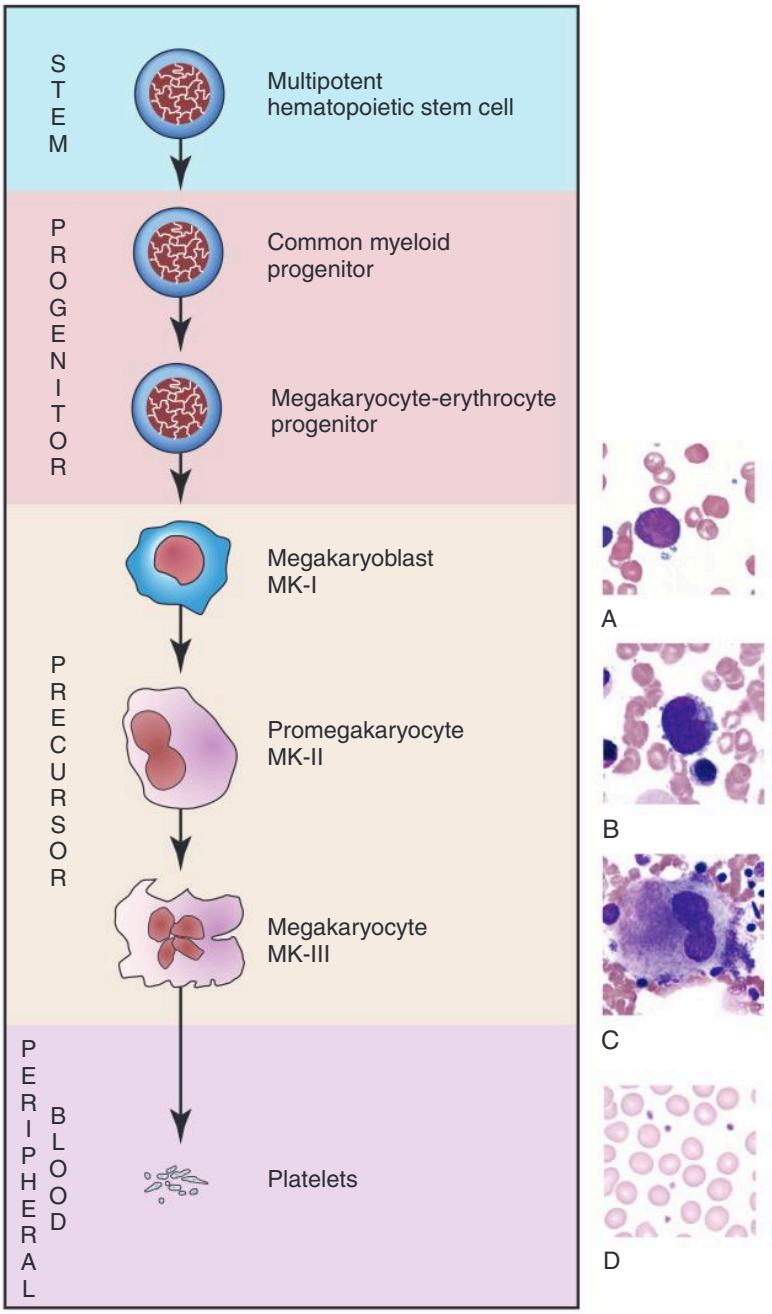


**FIGURE 4.9** Megakaryocyte sequence with: (A) megakaryoblast; (B) promegakaryocyte; (C) megakaryocyte; and (D) platelet.

CHAPTER 5

# NEUTROPHIL MATURATION

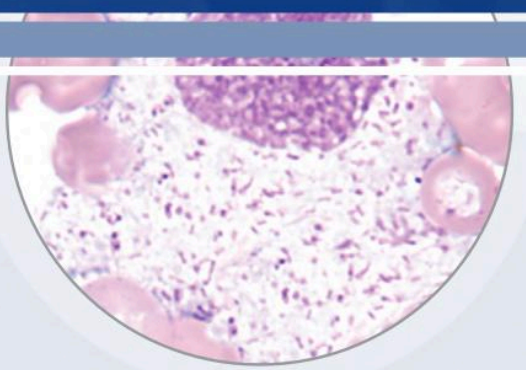

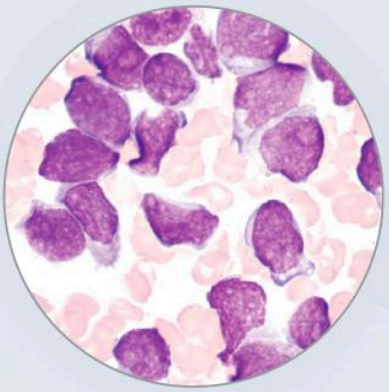

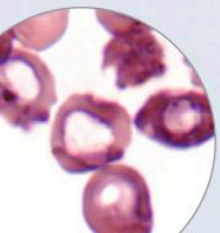

The common myeloid progenitor creates three types of progenitors: granulocytes/monocytes, eosinophils/basophils, and erythrocytes/megakaryocytes. Each of these divides and matures into cells known as *blasts*, one for each cell line. However, it is not possible to differentiate the various blasts at the light microscope level. This chapter addresses neutrophil maturation. (See Chapter 6, Eosinophil Maturation, for discussion of eosinophils and Chapter 7, Basophil Maturation, for discussion of basophils.)

As the cells mature from the myeloblast to the promyelocyte, there is a slight increase in size, in contrast with size variation in other cell lineages. At the promyelocyte stage, the chromatin in the nucleus becomes slightly coarser than the myeloblast, and primary burgundy-colored (azurophilic) granules appear in the cytoplasm. As the cell divides and matures to a myelocyte, chromatin becomes coarser and condensed, and secondary (specific) granules appear in the cytoplasm beginning at the Golgi apparatus and spreading throughout the cytoplasm. Primary granules are still present but less visible on a Wright-stained smear because of a chemical change in the membranes. It is often possible at the myelocyte stage to see the area of the Golgi apparatus, which appears as a clearing close to the nucleus. The specific secondary granules differentiate the cell into neutrophils, eosinophils, and basophils. The nucleus then begins to indent and chromatin becomes coarser, signaling the metamyelocyte stage. In the metamyelocyte, the indentation of the nucleus is less than 50% of the hypothetical round nucleus. The cell is called a *band* when the nucleus becomes constricted without threadlike filaments, and the indentation of the nucleus is more than 50% of the hypothetical round nucleus. Finally, the cell becomes a segmented neutrophil when the nucleus becomes segmented or lobated into two to five lobes. The lobes are connected by threadlike filaments with no chromatin visible in the filament.

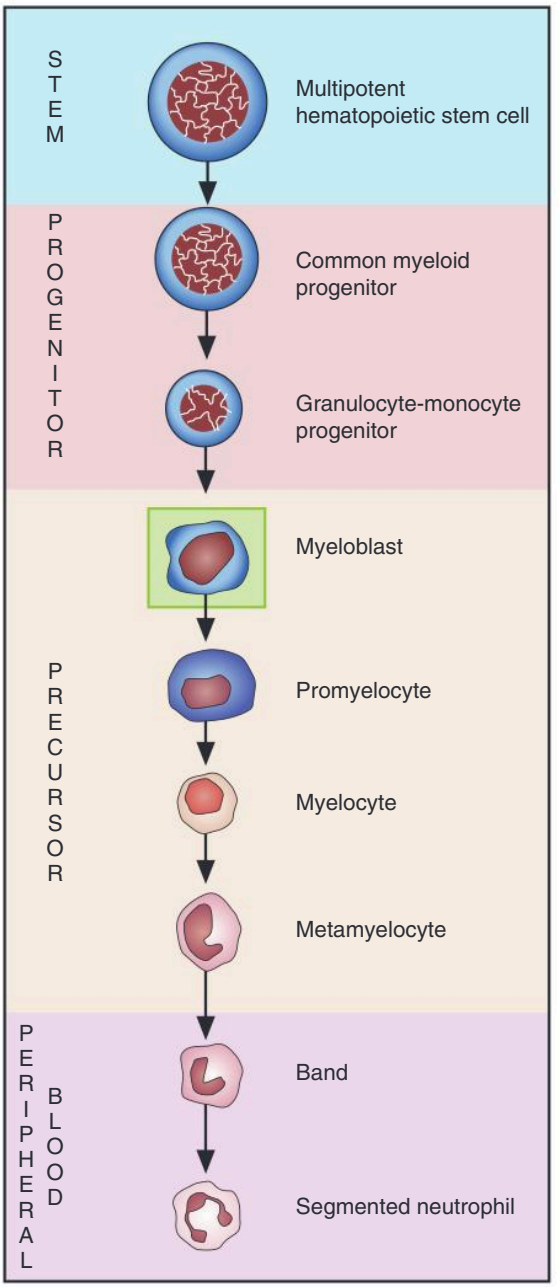


**FIGURE 5.1** Neutrophilic sequence: myeloblast.

The dynamic nature of maturation is easily seen in the neutrophilic series; that is, cell maturation does not proceed in a stepwise fashion but occurs gradually from one stage to another. Thus morphologically, a cell may appear as a late promyelocyte or an early myelocyte. When there is a question of maturation stage, it is generally preferable to classify the cell at the more mature stage.

## MYELOBLAST

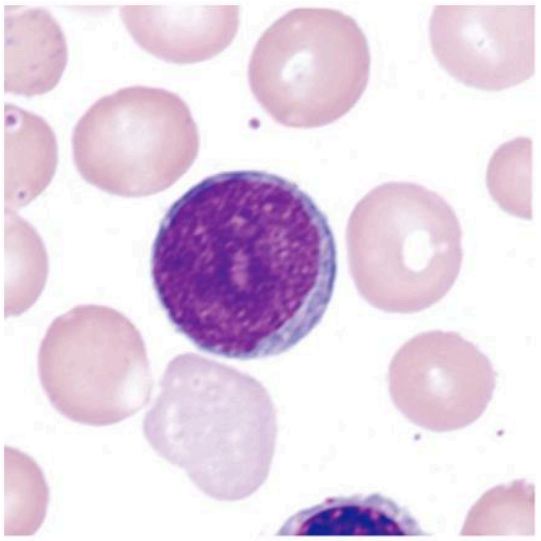

A

**FIGURE 5.2A** Myeloblast with no granules.

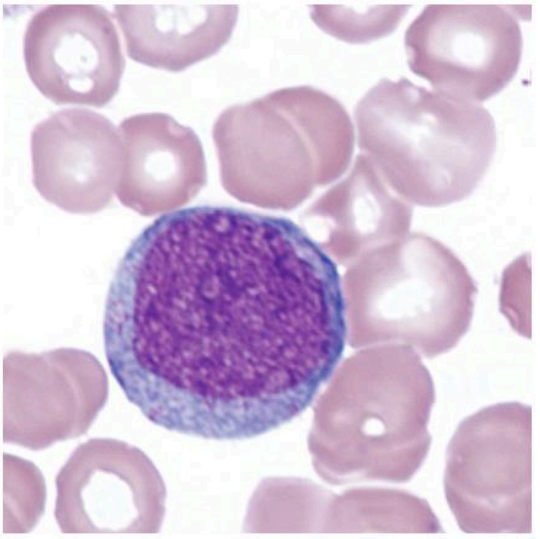

B

**FIGURE 5.2B** Myeloblast with up to 20 granules.

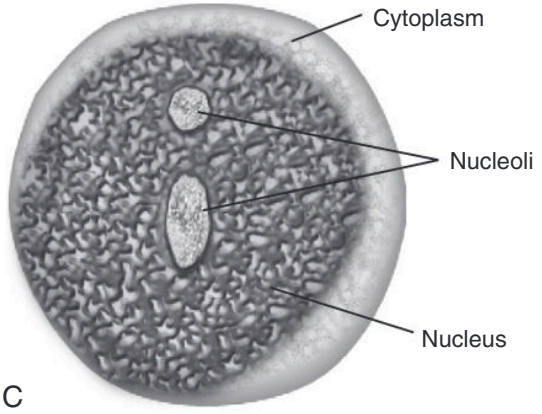


C

**FIGURE 5.2C** Schematic of Figure 5.2A, myeloblast.

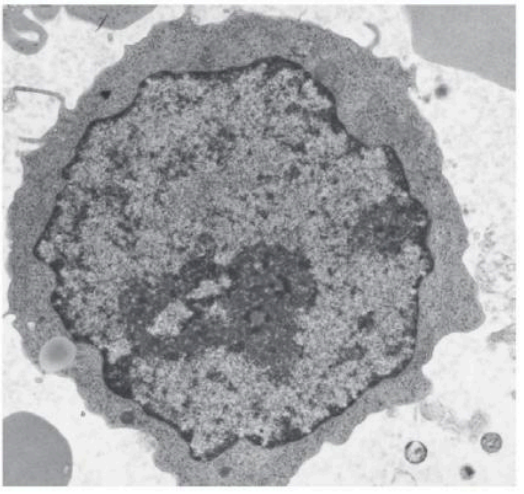

D

**FIGURE 5.2D** Electron micrograph of myeloblast (×16,500).

**SIZE:** 15 to 20 μm

**NUCLEUS:** Round to oval
**Nucleoli:** 2 to 5
**Chromatin:** Fine

**CYTOPLASM:** Moderate basophilia
**Granules:** Absent or up to 20

**N:C RATIO:** 4:1

**REFERENCE INTERVAL:**
**Bone Marrow:** 0% to 2%
**Peripheral Blood:** 0%

**NOTE:** Blasts without granulation are sometimes referred to as Type I blasts, and those with up to 20 granules as Type II blasts, although they are generally not separated as such in the differential count.

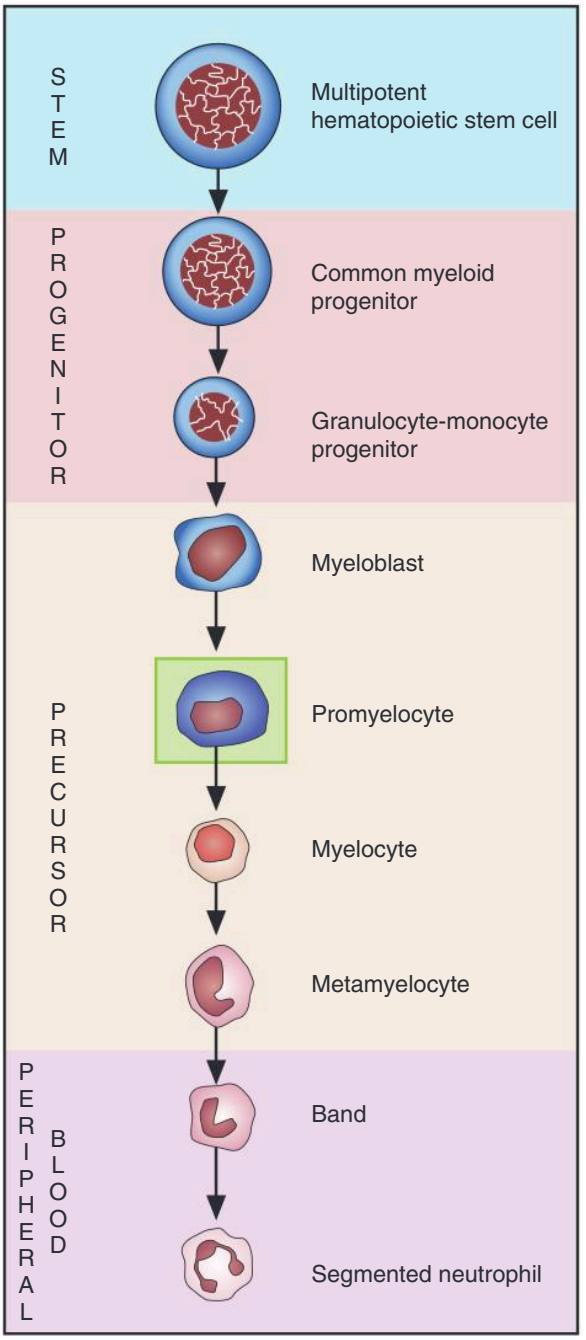


**FIGURE 5.3** Neutrophilic sequence: promyelocyte.

## PROMYELOCYTE (PROGRANULOCYTE)

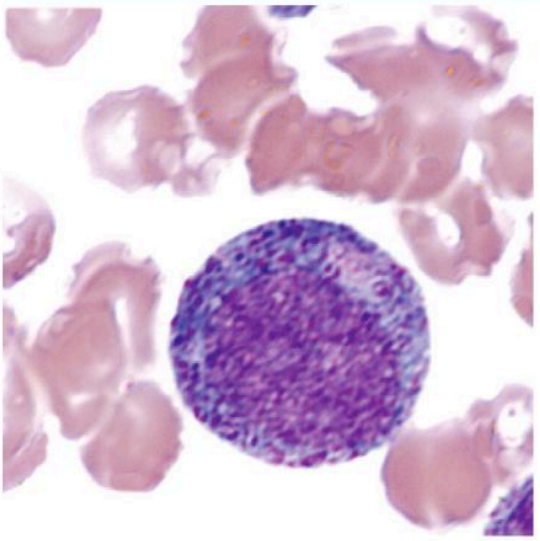

A

**FIGURE 5.4A** Promyelocyte.

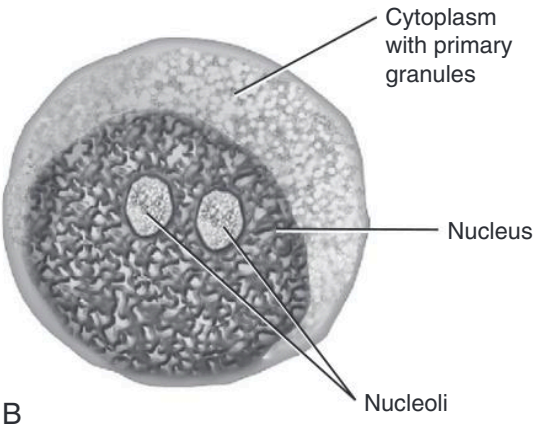


B

**FIGURE 5.4B** Schematic of promyelocyte.

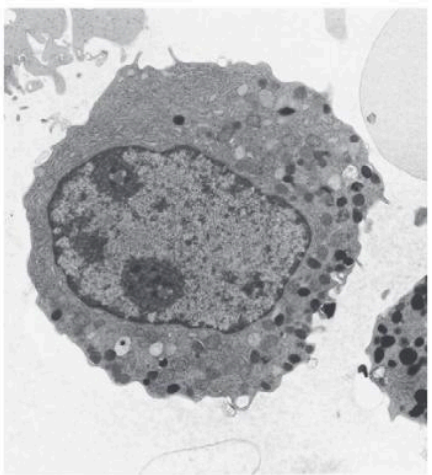

C

**FIGURE 5.4C** Electron micrograph of promyelocyte (×13,000).

**SIZE:** 14 to 24 μm (slightly larger than myeloblast)

**NUCLEUS:** Round to oval
**Nucleoli:** 1 to 3 or more
**Chromatin:** Fine, but slightly coarser than myeloblast

**CYTOPLASM:** Basophilic
**Granules:**
PRIMARY
More than 20; may be numerous; red to purple or burgundy
SECONDARY
None

**N:C RATIO:** 3:1

**REFERENCE INTERVAL:**
**Bone Marrow:** 2% to 5%
**Peripheral Blood:** 0%

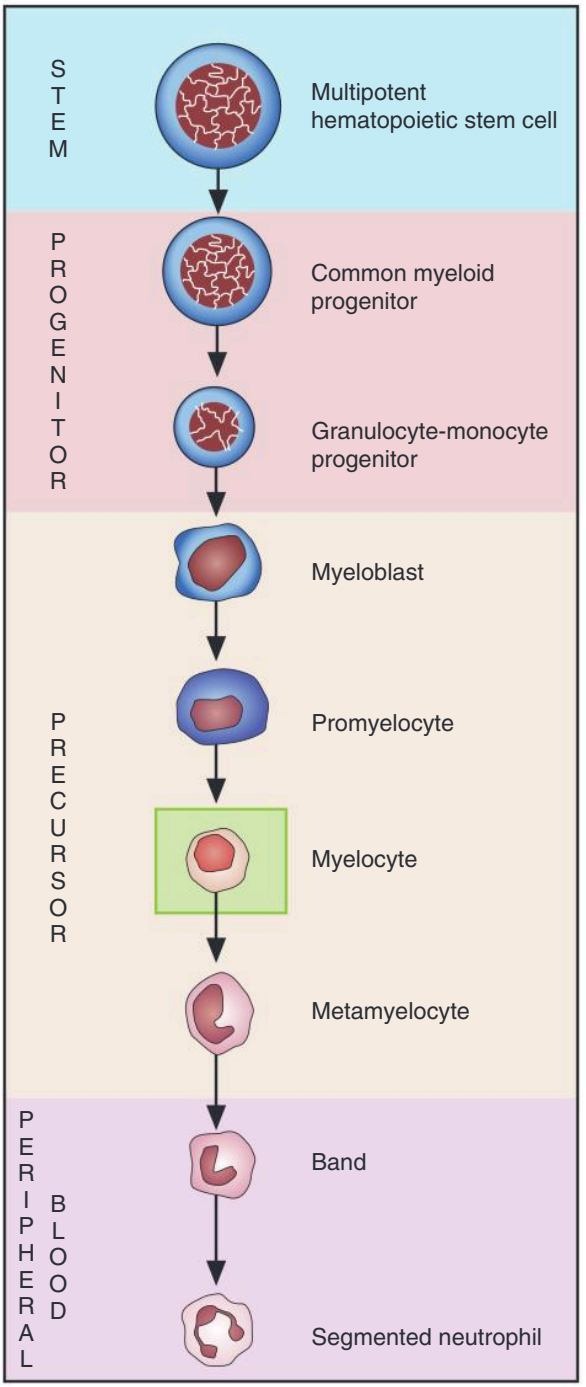


**FIGURE 5.5** Neutrophilic sequence: myelocyte.

## NEUTROPHILIC MYELOCYTE

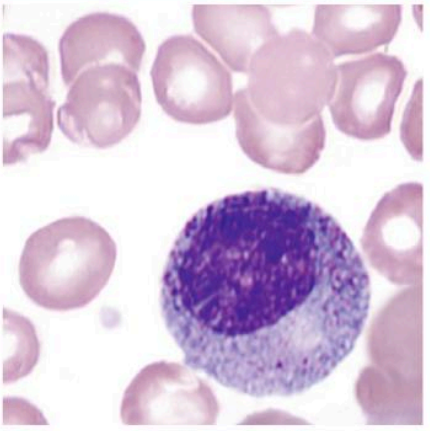

A

**FIGURE 5.6A** Neutrophilic myelocyte, early.

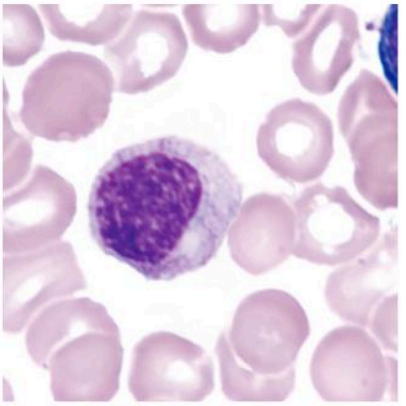

B

**FIGURE 5.6B** Neutrophilic myelocyte.

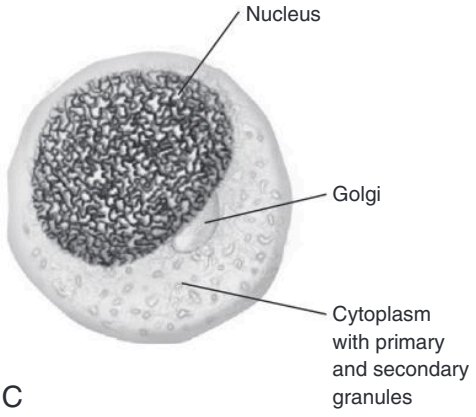


C

**FIGURE 5.6C** Schematic of myelocyte.

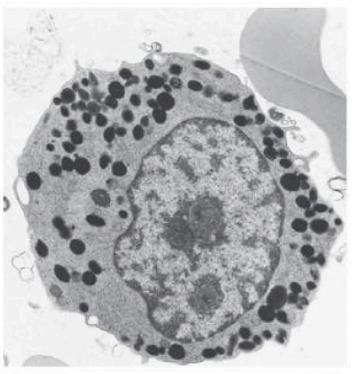

D

**FIGURE 5.6D** Electron micrograph of myelocyte (×16,500).

**SIZE:** 12 to 18 μm

**NUCLEUS:** Round to oval; slightly eccentric; may have one flattened side; may have a clearing next to the nucleus indicating the location of the Golgi

**Nucleoli:** Usually not visible

**Chromatin:** Coarse and more condensed than promyelocyte

**CYTOPLASM:** Slightly basophilic, to cream-colored

**Granules:**

PRIMARY

Few to moderate

SECONDARY

Variable number; becoming predominant as cell matures

**N:C RATIO:** 2:1

**REFERENCE INTERVAL:**

**Bone Marrow:** 5% to 19%

**Peripheral Blood:** 0%

**NOTE:** Secondary granules in neutrophils are too small to resolve at the light microscope level. They give the cytoplasm a grainy or sandy appearance, and the overall color is lavender to pink. (See Figure 7.2 for eosinophilic myelocyte.)

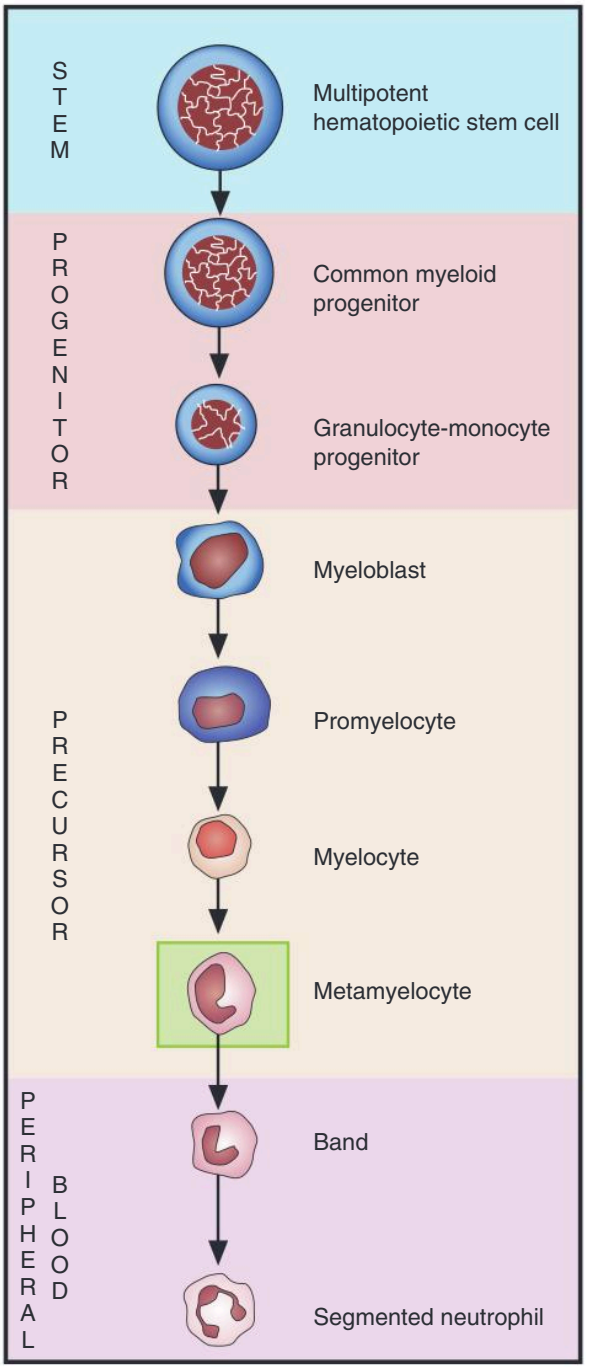


**FIGURE 5.7** Neutrophilic sequence: metamyelocyte.

## NEUTROPHILIC METAMYELOCYTE

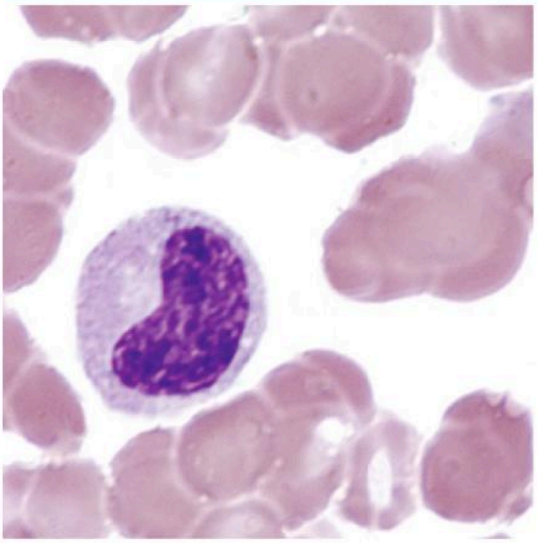

A

**FIGURE 5.8A** Neutrophilic metamyelocyte.

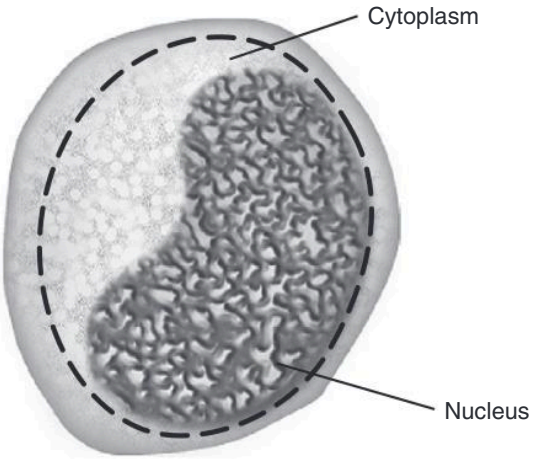


B

**FIGURE 5.8B** Schematic of metamyelocyte. *Dotted line* indicates hypothetical round nucleus.

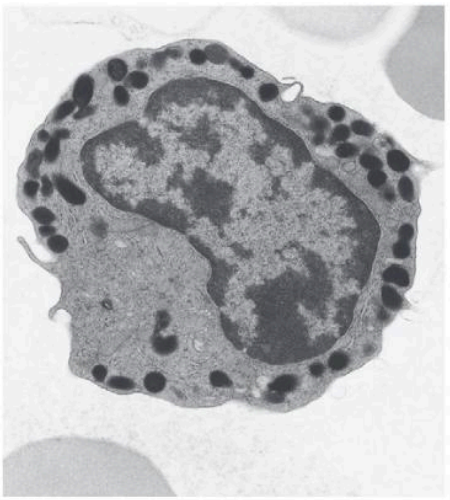

C

**FIGURE 5.8C** Electron micrograph of metamyelocyte (×22,250).

**SIZE:** 10 to 15 μm

**NUCLEUS:** Indented; kidney bean shape; indentation is less than 50% of the width of a hypothetical round nucleus
**Nucleoli:** Not visible
**Chromatin:** Moderately clumped

**CYTOPLASM:** Pale pink, to cream colored, to colorless
**Granules:**
PRIMARY
Few
SECONDARY
Many (full complement)

**N:C RATIO:** 1.5:1

**REFERENCE INTERVAL:**
**Bone Marrow:** 13% to 22%
**Peripheral Blood:** 0%

See Figure 7.4 for eosinophilic metamyelocyte.

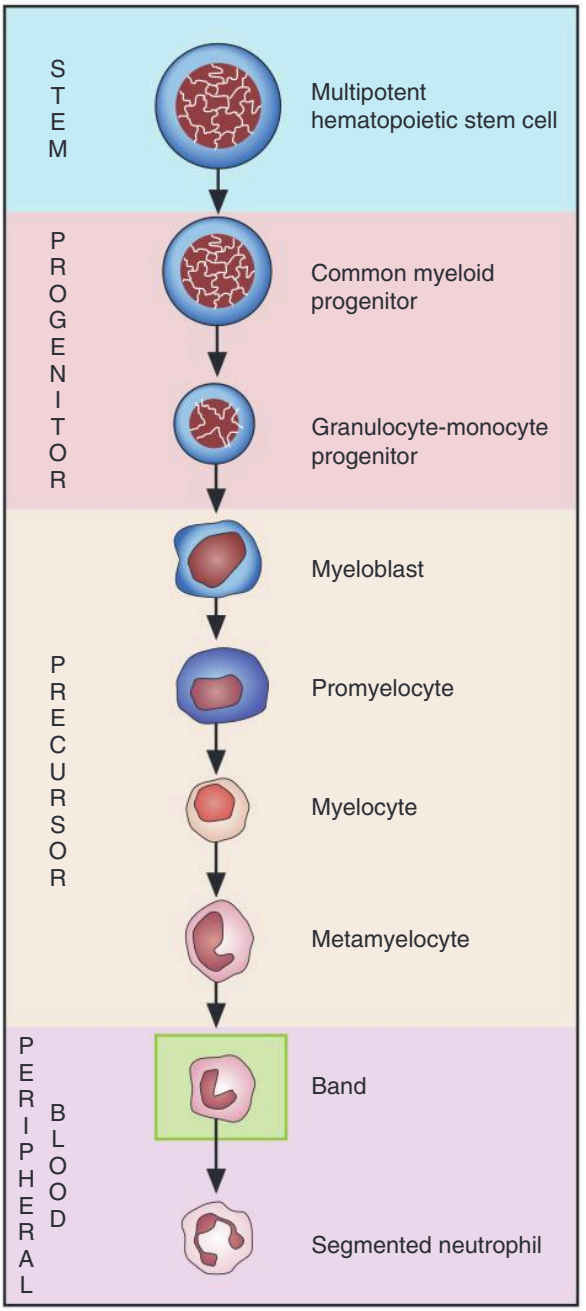


**FIGURE 5.9** Neutrophilic sequence: band.

## NEUTROPHILIC BAND

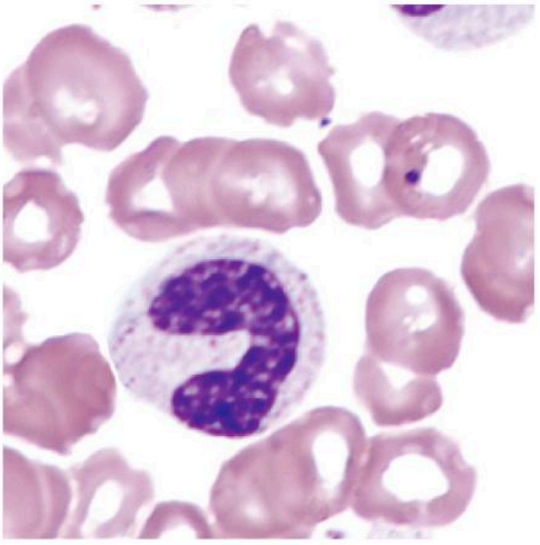

A

**FIGURE 5.10A** Neutrophilic band.



C

**FIGURE 5.10C** Electron micrograph of band (×22,250).

**NOTE:** There is so much variability in the differentiation of band neutrophils from segmented neutrophils that the College of American Pathologists does not require that they be differentiated for proficiency testing.*

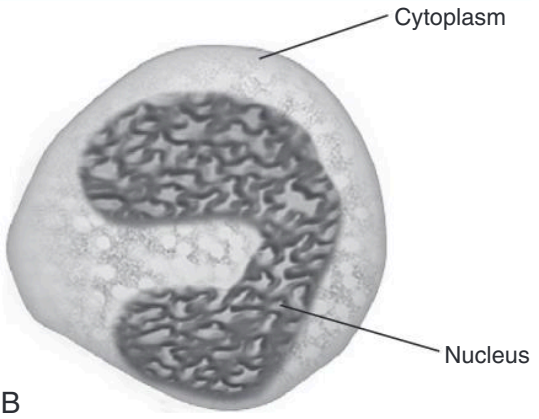


B

**FIGURE 5.10B** Schematic of band.

**SIZE:** 10 to 15 μm

**NUCLEUS:** Constricted but no threadlike filament; indentation is more than 50% of the width of a hypothetical round nucleus

**NOTE:** Chromatin must be visible in constriction; may be folded over.

**Nucleoli:** Not visible
**Chromatin:** Coarse, clumped

**CYTOPLASM:** Pale pink, to colorless
**Granules:**
PRIMARY
Few
SECONDARY
Abundant

**N:C RATIO:** Cytoplasm predominates

**REFERENCE INTERVAL:**
**Bone Marrow:** 17% to 33%
**Peripheral Blood:** 0% to 5%

Refer to Table 1.1 for more examples.
See Figure 7.6 for eosinophilic band.

*The College of American Pathologists recommendations are available at: College of American Pathologists. Blood cell identification. In *2019 Hematology and clinical microscopy glossary* . Northfield, IL, 2015, College of American Pathologists.

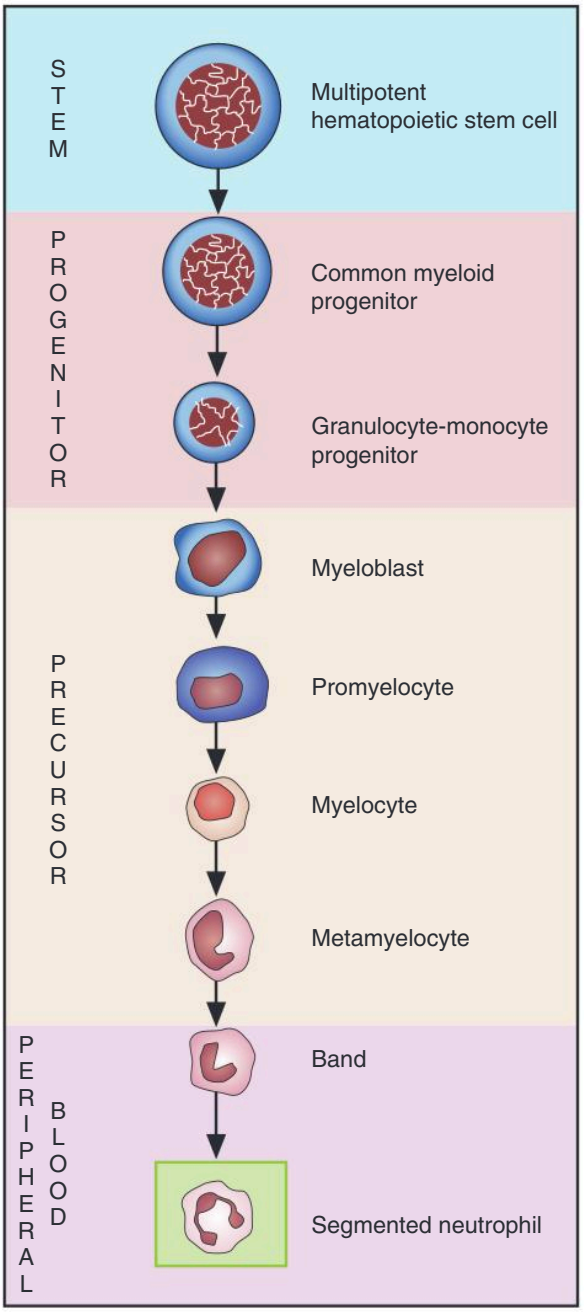


**FIGURE 5.11** Neutrophilic sequence: segmented neutrophil.

## SEGMENTED NEUTROPHIL

### Polymorphonuclear Neutrophil

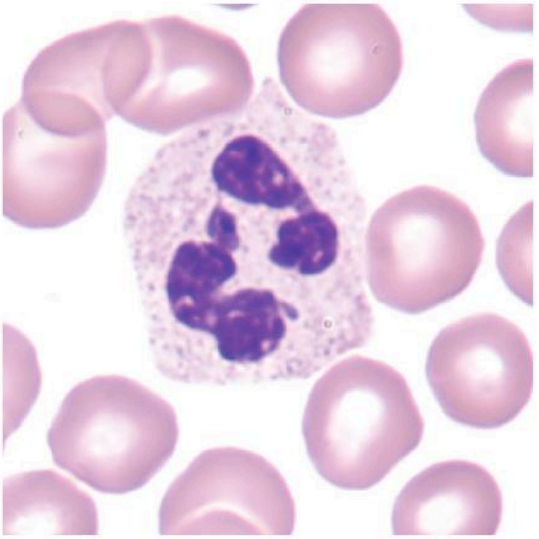

A

**FIGURE 5.12A** Segmented neutrophil.

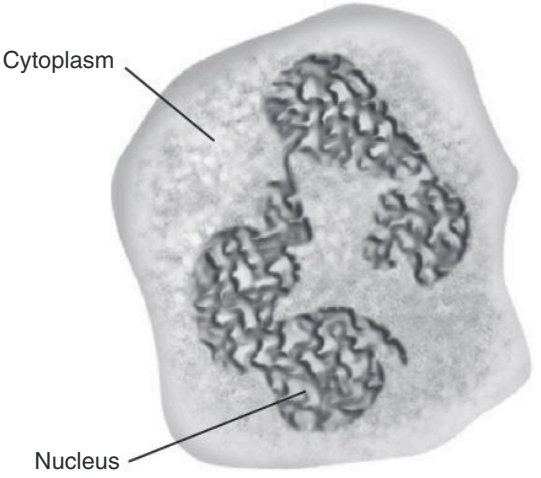


B

**FIGURE 5.12B** Schematic of segmented neutrophil.

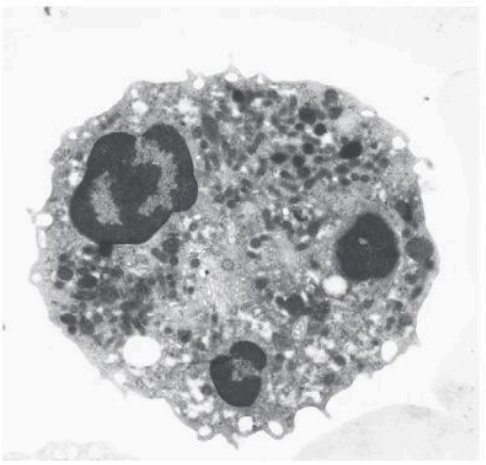

C

**FIGURE 5.12C** Electron micrograph of segmented neutrophil (×22,250). Specimens for electron microscopy are prepared by embedding tissue in a suitable medium, such as resin. Ultra-thin cross sections are then prepared. Because this image shows a cross section, the lobes of the nucleus appear to be separate, but are not.

**SIZE:** 10 to 15 μm

**NUCLEUS:** 2 to 5 lobes connected by thin filaments, without visible chromatin
**Nucleoli:** Not visible
**Chromatin:** Coarse, clumped

**CYTOPLASM:** Pale pink, cream-colored, or colorless
**Granules:**
PRIMARY
Rare
SECONDARY
Abundant

**N:C RATIO:** Cytoplasm predominates

**REFERENCE INTERVAL:**
**Bone Marrow:** 3% to 11%
**Peripheral Blood:** 50% to 70%

Refer to Table 1.1 for more examples.

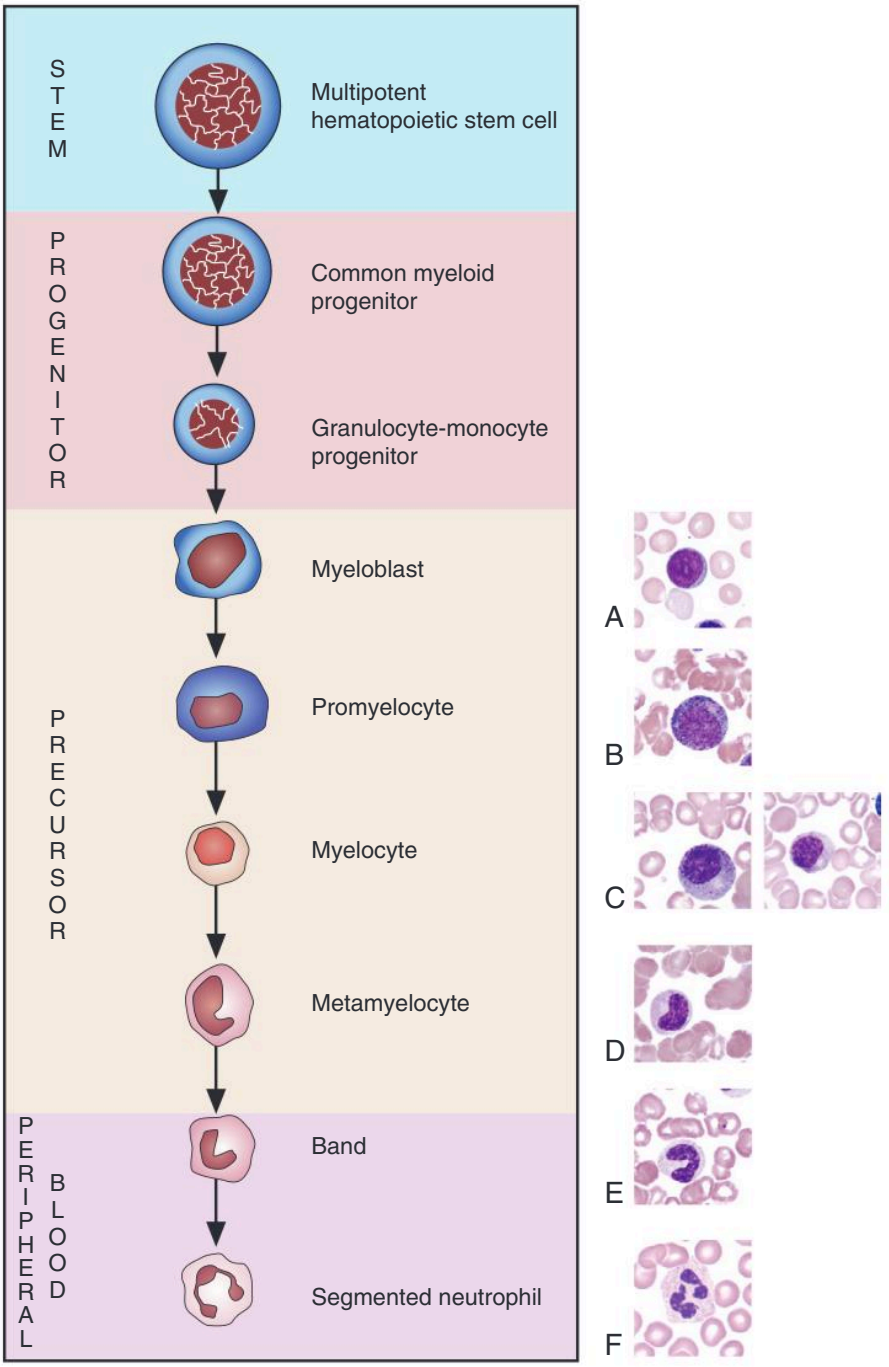


**FIGURE 5.13** Neutrophilic sequence with: (A) myeloblast; (B) promyelocyte; (C) myelocyte; (D) metamyelocyte; (E) band; and (F) segmented neutrophil.

CHAPTER 6

# EOSINOPHIL MATURATION

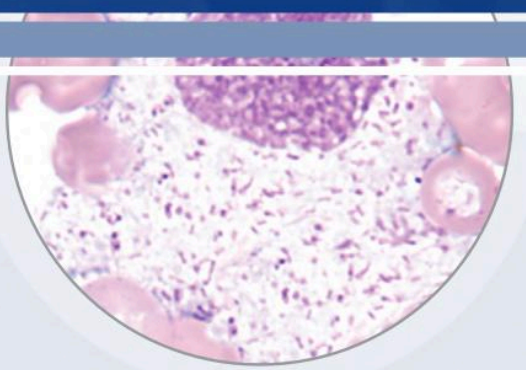

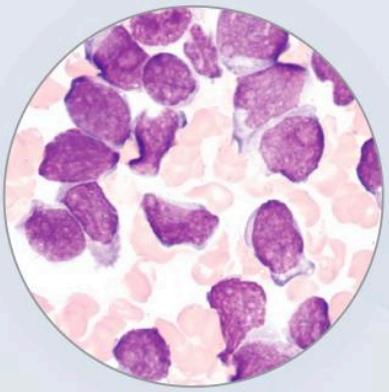

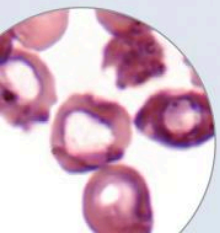

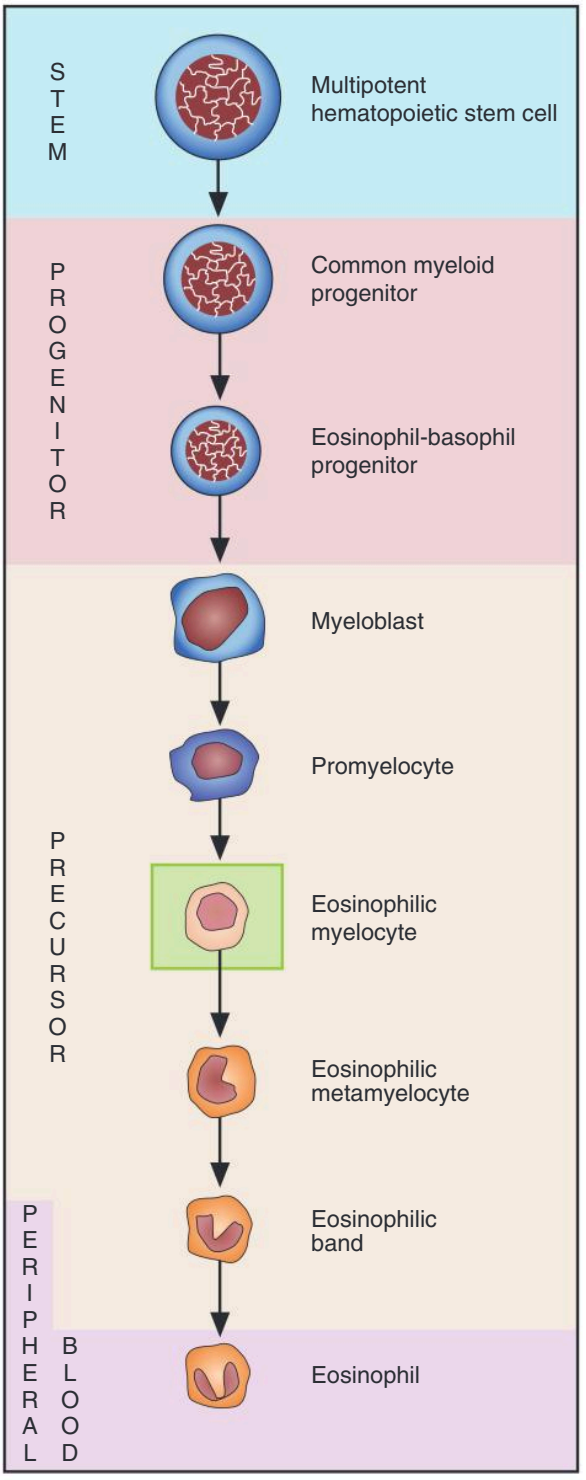


**FIGURE 6.1** Eosinophilic sequence: eosinophilic myelocyte.

All photomicrographs are ×1000 original magnification with Wright-Giemsa staining unless stated otherwise.

## EOSINOPHILIC MYELOCYTE

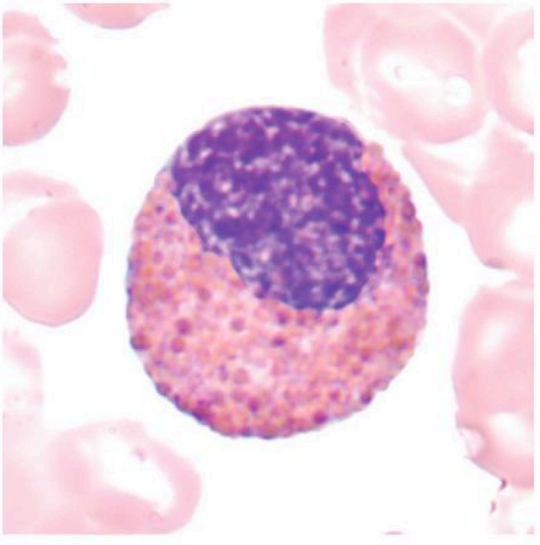

A

**FIGURE 6.2A** Eosinophilic myelocyte.

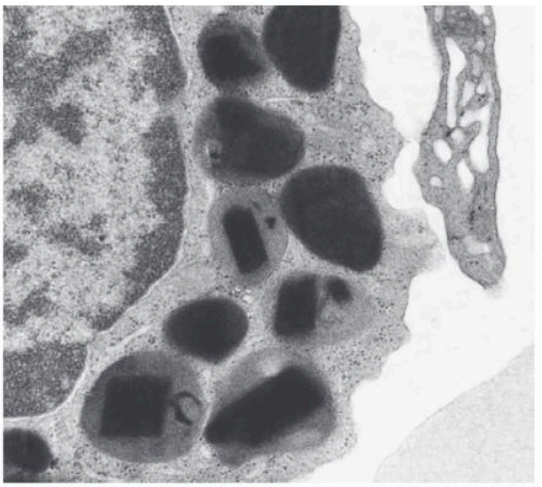

B

**FIGURE 6.2B** Electron micrograph of eosinophilic granules to demonstrate crystalline structure of granules.

**SIZE:** 12 to 18 μm

**NUCLEUS:** Round to oval; may have one flattened side
**Nucleoli:** Usually not visible
**Chromatin:** Coarse and more condensed than promyelocyte

**CYTOPLASM:** Colorless to pink
**Granules:**
PRIMARY
Few to moderate
SECONDARY
Variable number; pale orange to dark orange; round; appear refractile

**N:C RATIO:** 2:1 to 1:1

**REFERENCE INTERVAL:**
**Bone Marrow:** 0% to 2%
**Peripheral Blood:** 0%

**NOTE:** This chapter begins with the image of the myelocyte, rather than the blast, because it is at the myelocyte stage that secondary granules, which define a cell as an eosinophil, first appear.

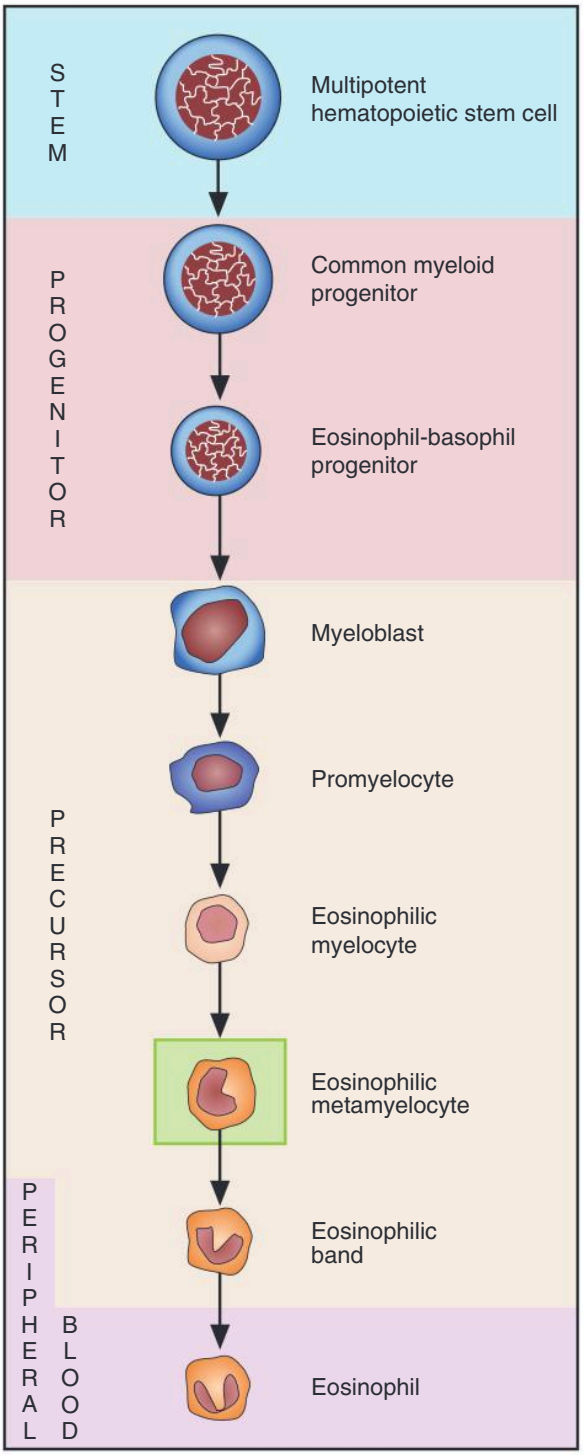


**FIGURE 6.3** Eosinophilic sequence: eosinophilic metamyelocyte.

## EOSINOPHILIC METAMYELOCYTE

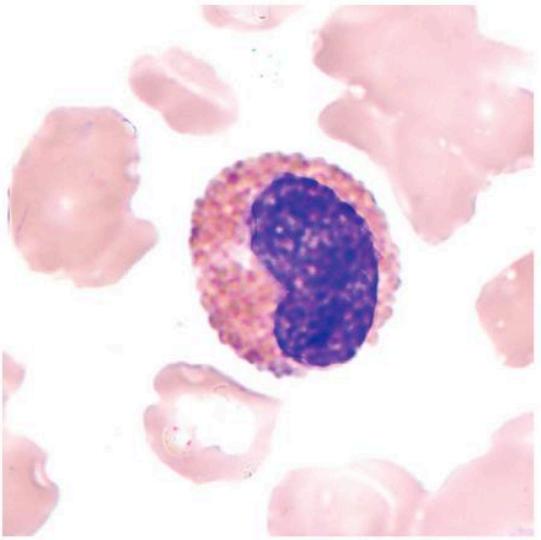

**FIGURE 6.4** Eosinophilic metamyelocyte.

**SIZE:** 10 to 15 μm

**NUCLEUS:** Indented; kidney-bean shape; indentation is less than 50% of the width of the hypothetical round nucleus
**Nucleoli:** Not visible
**Chromatin:** Coarse, clumped

**CYTOPLASM:** Colorless, cream colored
**Granules:**
PRIMARY
Few
SECONDARY
Many pale orange to dark orange; appear refractile

**N:C RATIO:** 1.5:1

**REFERENCE INTERVAL:**
**Bone Marrow:** 0% to 2%
**Peripheral Blood:** 0%

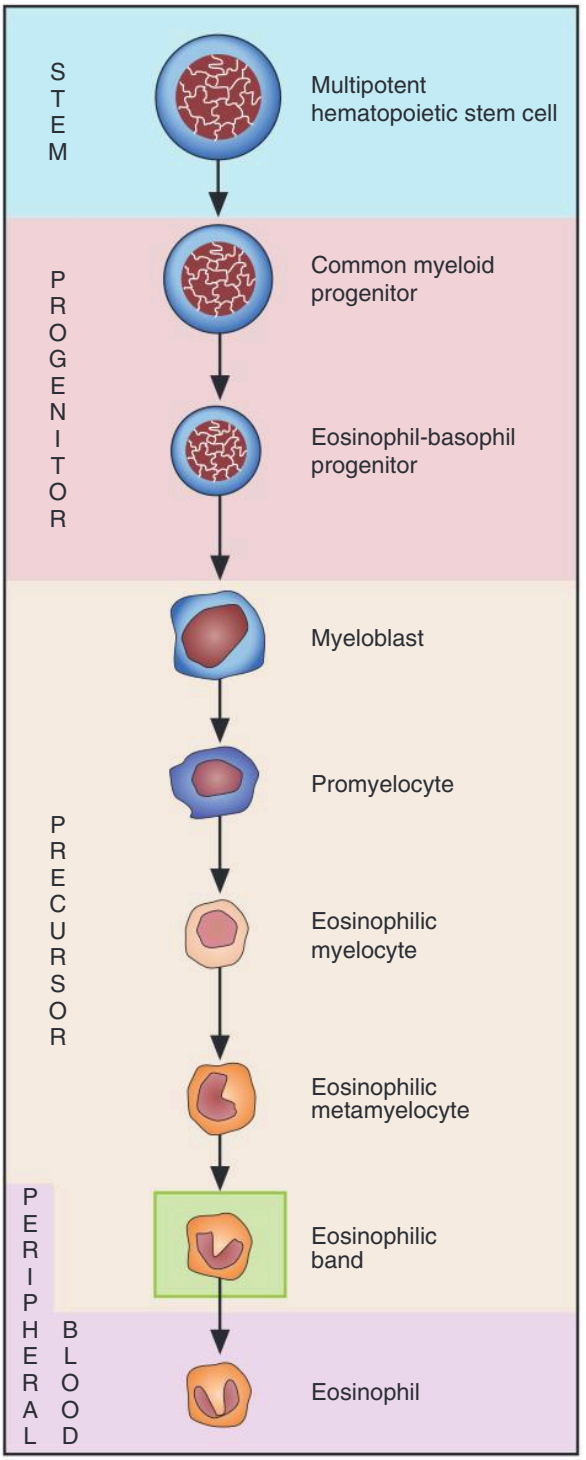


**FIGURE 6.5** Eosinophilic sequence: eosinophilic band.

## EOSINOPHILIC BAND

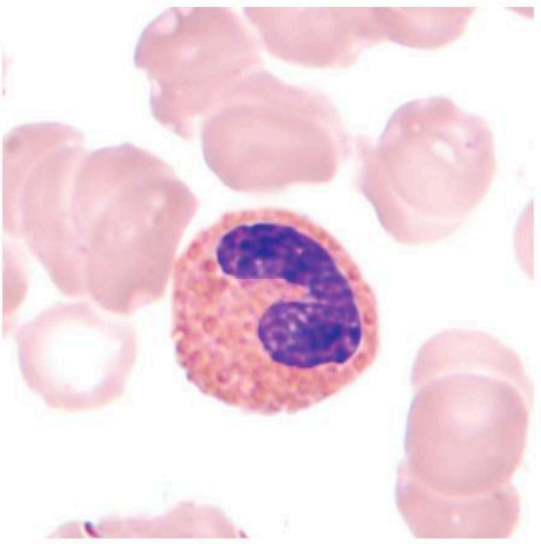

**FIGURE 6.6** Eosinophilic band.

**SIZE:** 10 to 15 μm

**NUCLEUS:** Constricted but no threadlike filament; indentation is more than 50% of the width of a hypothetical round nucleus

**NOTE:** Chromatin must be visible in constriction.

**Nucleoli:** Not visible
**Chromatin:** Coarse, clumped

**CYTOPLASM:** Colorless, cream colored
**Granules:**
PRIMARY
Few
SECONDARY
Abundant pale to dark orange; appear refractile

**N:C RATIO:** Cytoplasm predominates

**REFERENCE INTERVAL:**
**Bone Marrow:** 0% to 2%
**Peripheral Blood:** Rarely seen

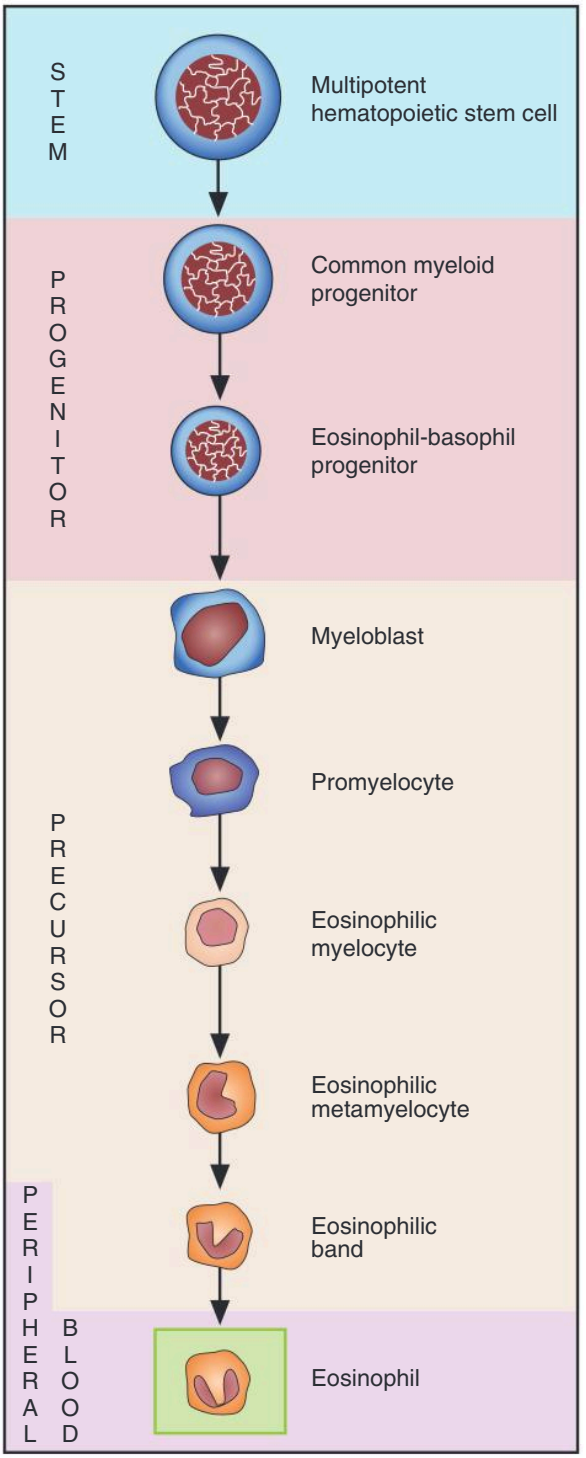


**FIGURE 6.7** Eosinophilic sequence: eosinophil.

## EOSINOPHIL

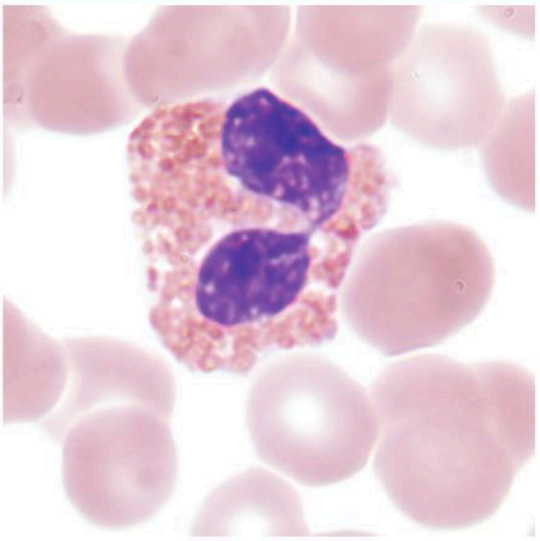

A

**FIGURE 6.8A** Eosinophil.

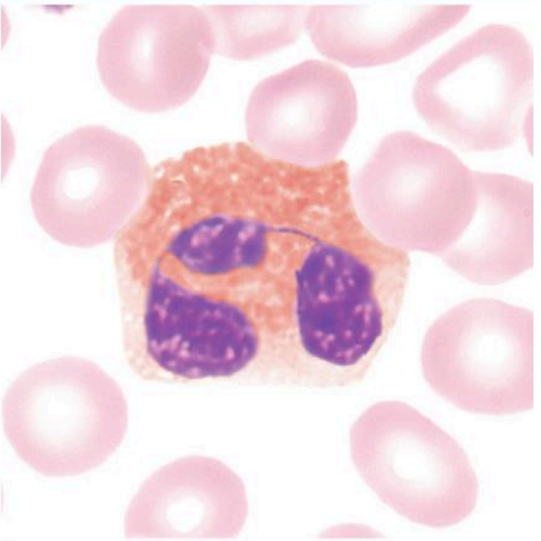

B

**FIGURE 6.8B** Eosinophil with 3 lobes.

**SIZE:** 12 to 17 μm

**NUCLEUS:** Two to three lobes connected by thin filaments without visible chromatin; majority of mature cells have two lobes
**Nucleoli:** Not visible
**Chromatin:** Coarse, clumped

**CYTOPLASM:** Cream colored; may have irregular borders
**Granules:**
PRIMARY
Rare
SECONDARY
Abundant pale orange to dark orange; appear refractile

**N:C RATIO:** Cytoplasm predominates

**REFERENCE INTERVAL:**
**Bone Marrow:** 0% to 3%
**Peripheral Blood:** 0% to 5%

Refer to Table 1.1 for more examples.

**NOTE:** Eosinophils are fragile and may easily fracture when preparing blood film.

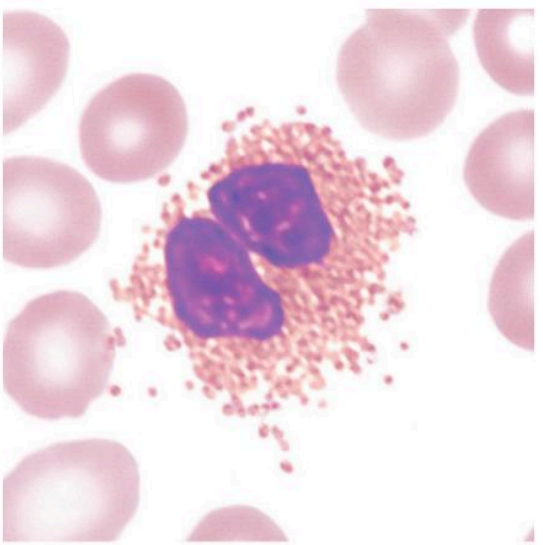

C

**FIGURE 6.8C** Fractured eosinophil.

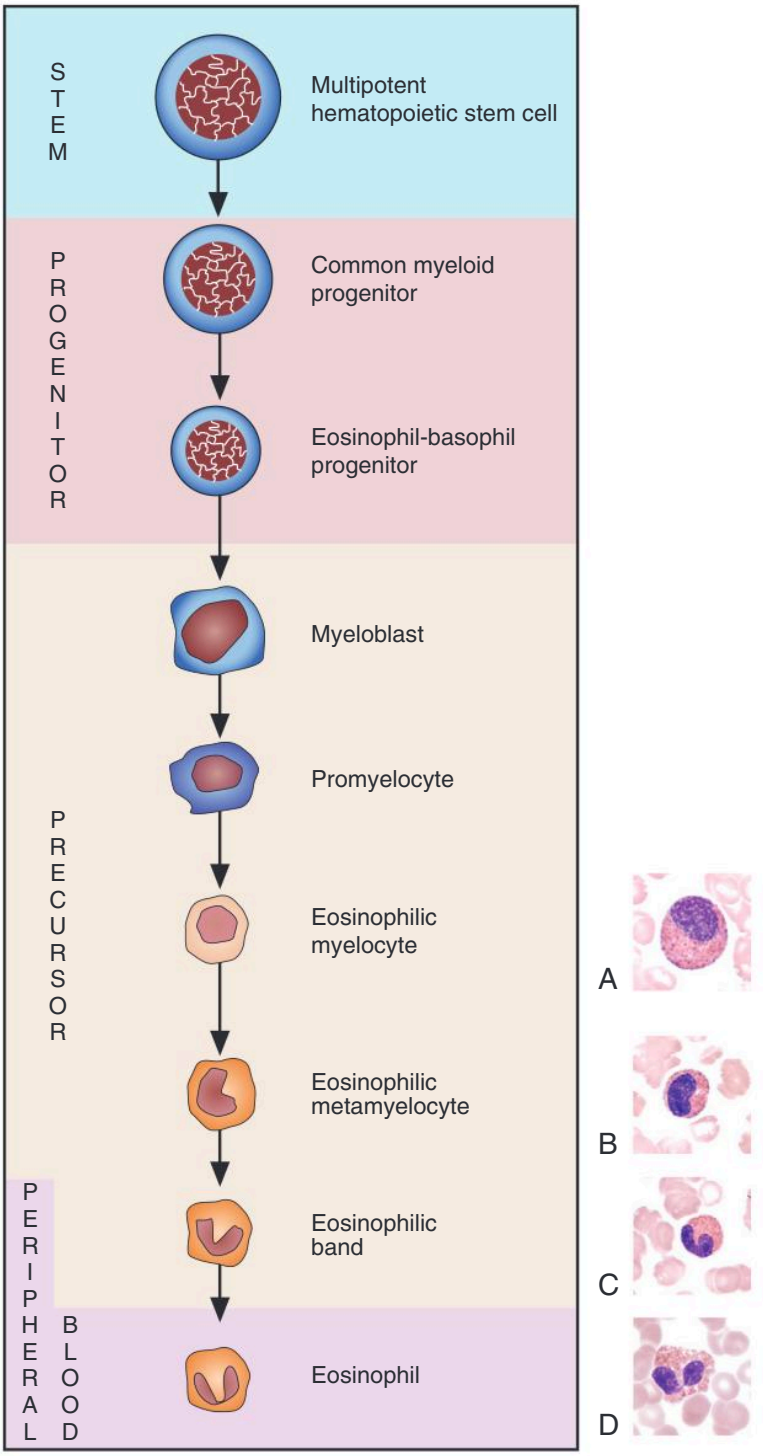


**FIGURE 6.9** Eosinophilic sequence with: (A) eosinophilic myelocyte; (B) eosinophilic metamyelocyte; (C) eosinophilic band; and (D) eosinophil.

CHAPTER 7

# BASOPHIL MATURATION

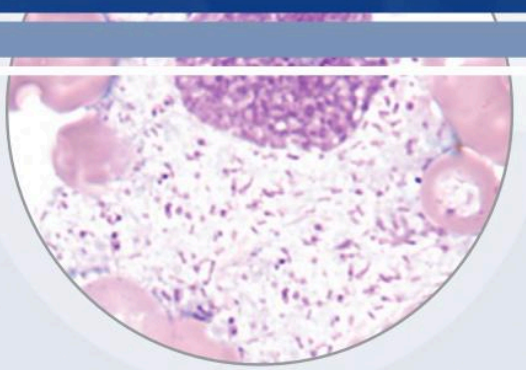

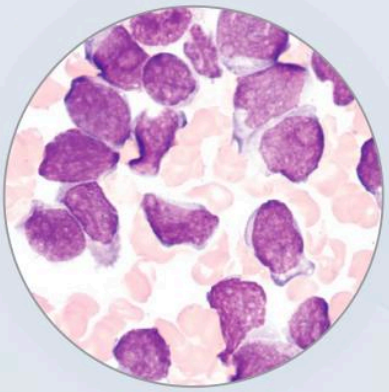

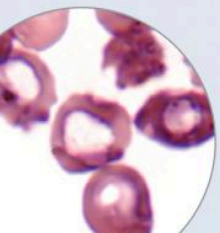

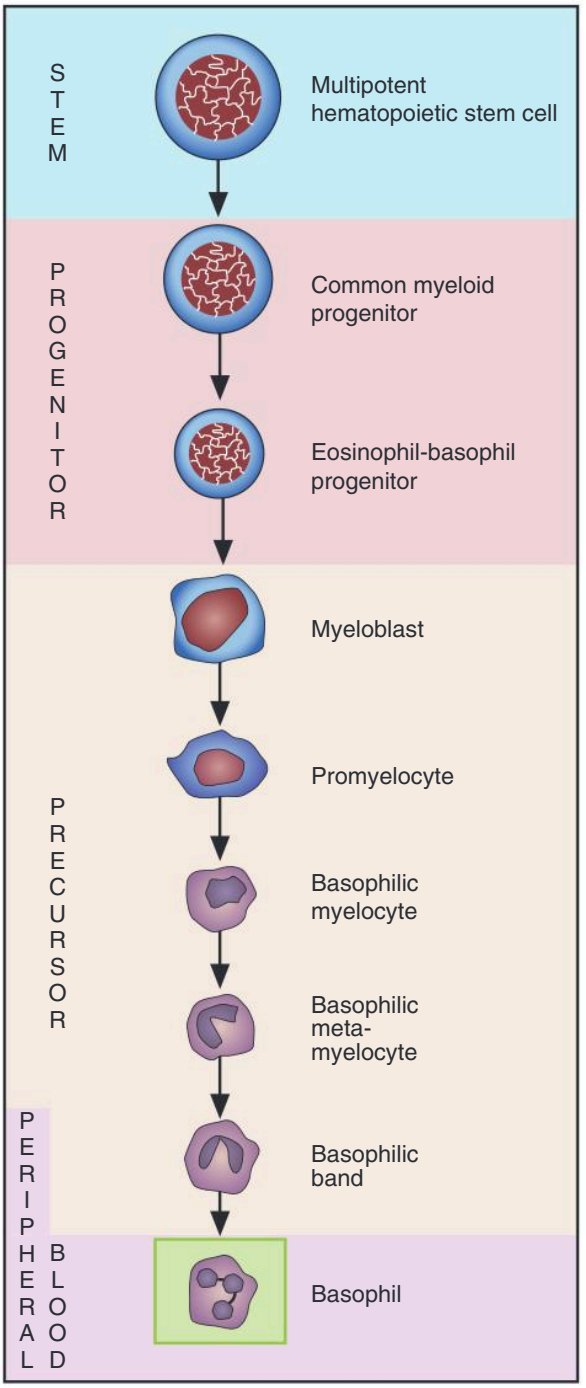


**FIGURE 7.1** Basophilic sequence: Basophil. Maturation parallels that of the neutrophil; however, immature stages are very rare and generally seen only in basophil proliferative disorders.

All photomicrographs are ×1000 original magnification with Wright-Giemsa staining unless stated otherwise.

## BASOPHIL

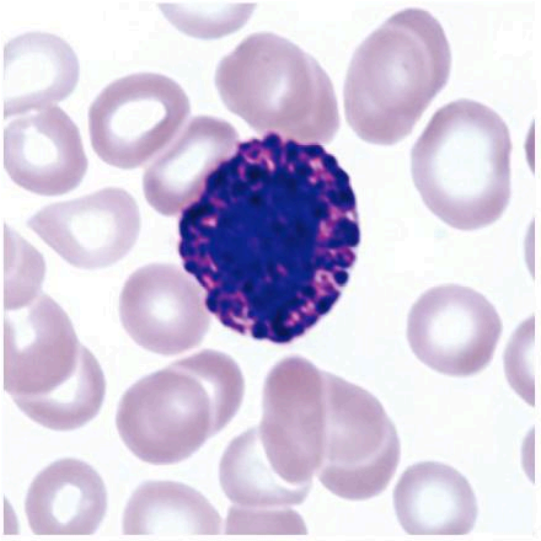

A

**FIGURE 7.2A** Basophil.

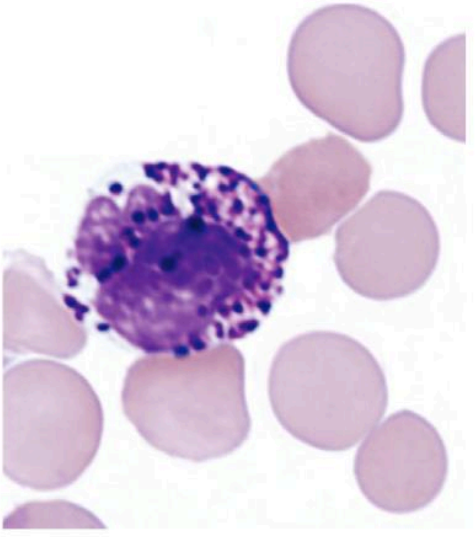

B

**FIGURE 7.2B** Basophil. Note that granules are water soluble and may be dissolved during the staining process, leaving clear areas in the cytoplasm.

**SIZE:** 10 to 14 μm

**NUCLEUS:** Usually two lobes connected by thin filaments without visible chromatin
**Nucleoli:** Not visible
**Chromatin:** Coarse, clumped

**CYTOPLASM:** Lavender to colorless
**Granules:**
PRIMARY
Rare
SECONDARY
Large, variable in number with uneven distribution, may obscure nucleus (Figure 7.2A); deep purple to black; irregularly shaped. Granules are water soluble and may be washed out during staining; thus they appear as empty areas in the cytoplasm (Figure 7.2B).

**N:C RATIO:** Cytoplasm predominates

**REFERENCE INTERVAL:**
**Bone Marrow:** Less than 1%
**Peripheral Blood:** 0% to 1%

Refer to Table 1.1 for more examples.

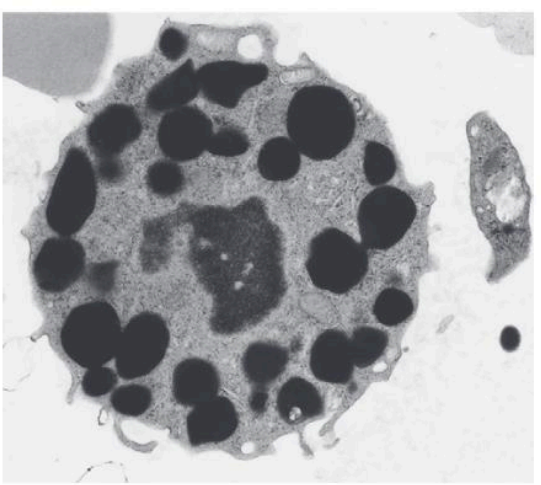

C

**FIGURE 7.2C** Electron micrograph of basophil (×28,750).

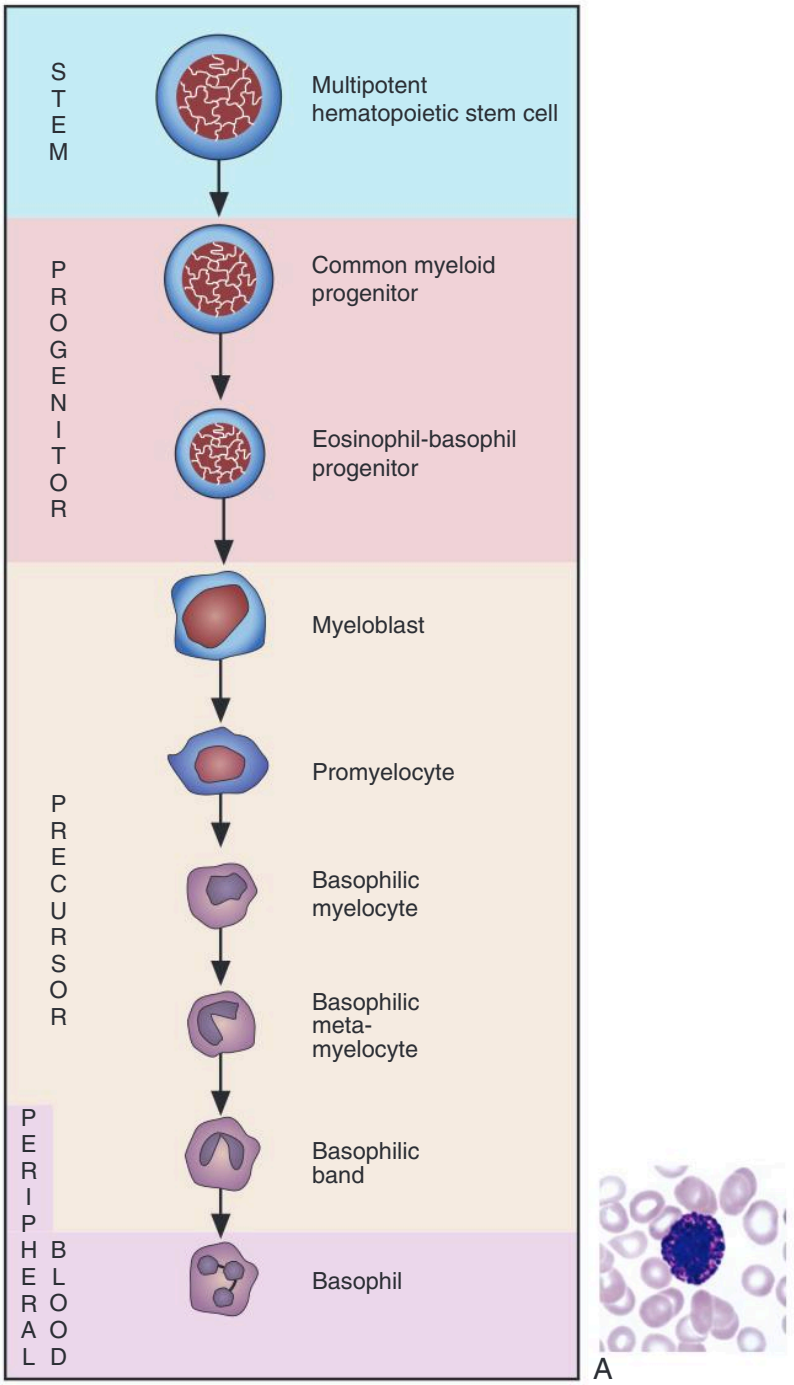


**FIGURE 7.3** Maturation parallels that of the neutrophil; however, immature stages are very rare and generally seen only in basophil proliferative disorders. (A) Basophil.

CHAPTER 8

# MONOCYTE MATURATION

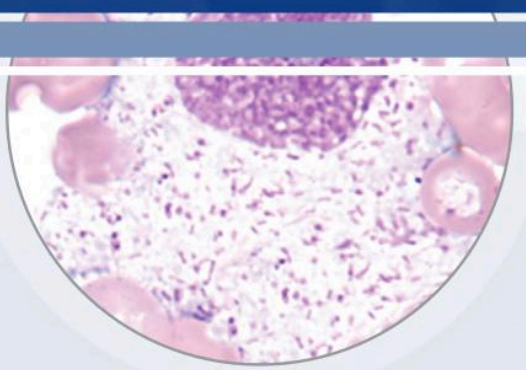

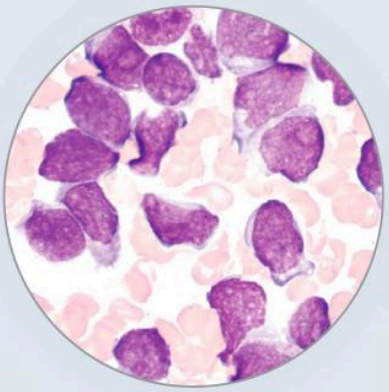

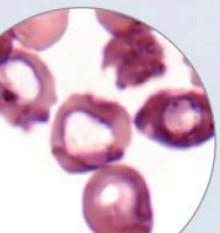

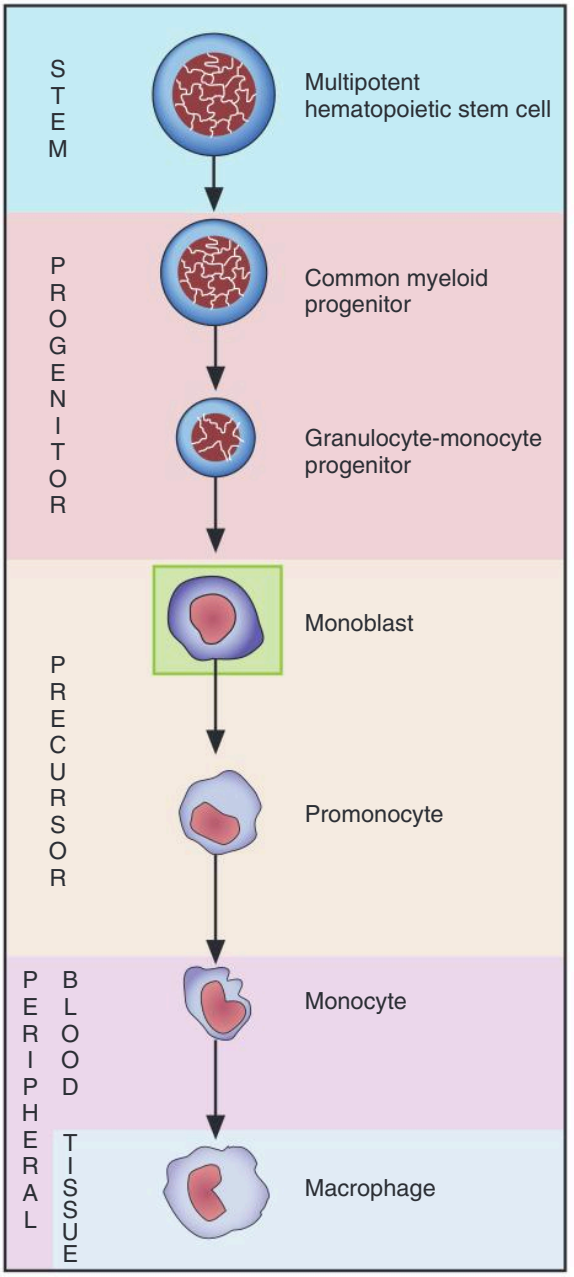


**FIGURE 8.1** Monocyte sequence: monoblast.

All photomicrographs are ×1000 original magnification with Wright-Giemsa staining unless stated otherwise.

## MONOBLAST

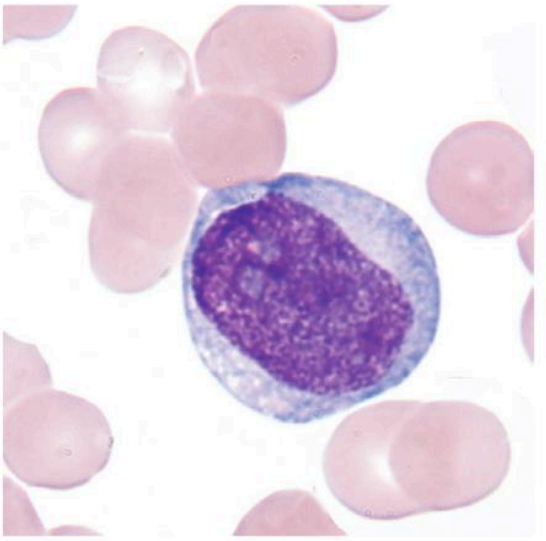

A

**FIGURE 8.2A** Monoblast.

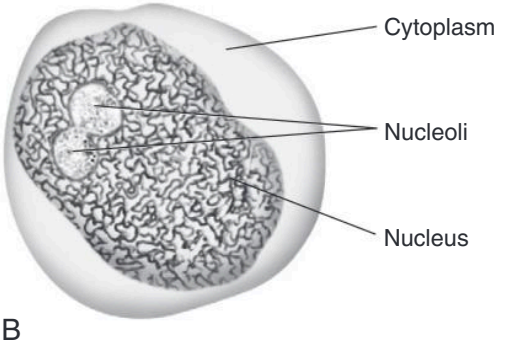


B

**FIGURE 8.2B** Schematic of monoblast.

**SIZE:** 12 to 18 μm

**NUCLEUS:** Round to oval; may be irregularly shaped
**Nucleoli:** 1 to 2; may not be visible
**Chromatin:** Fine

**CYTOPLASM:** Light blue to gray
**Granules:** None

**N:C RATIO:** 4:1

**REFERENCE INTERVAL:**
**Bone Marrow:** Not defined
**Peripheral Blood:** 0%

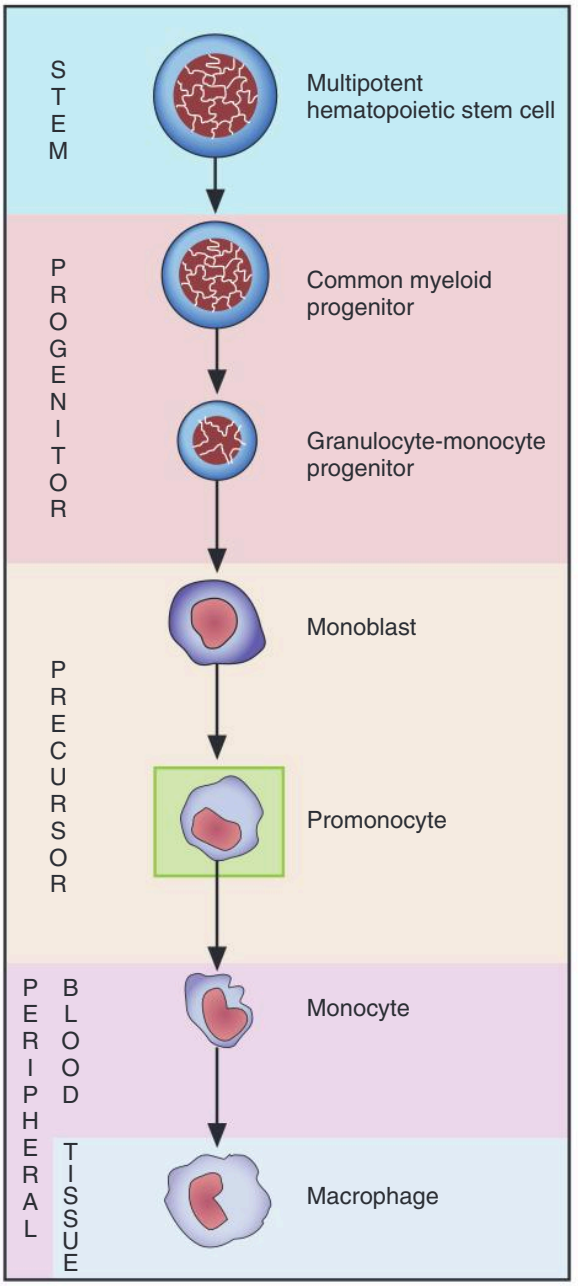


**FIGURE 8.3** Monocyte sequence: promonocyte.

## PROMONOCYTE

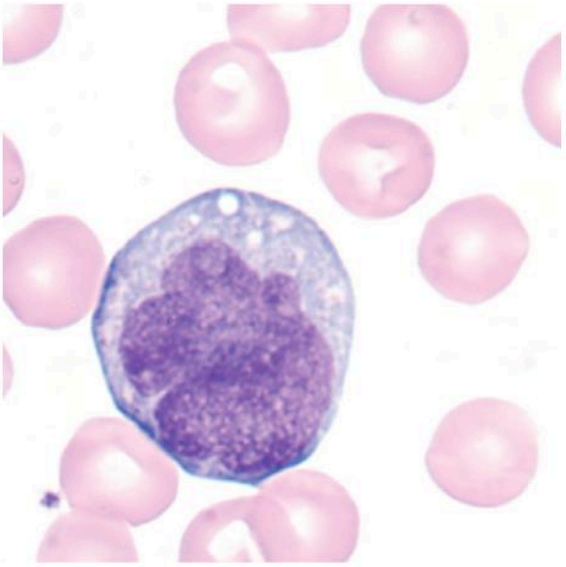

A

**FIGURE 8.4A** Promonocyte.

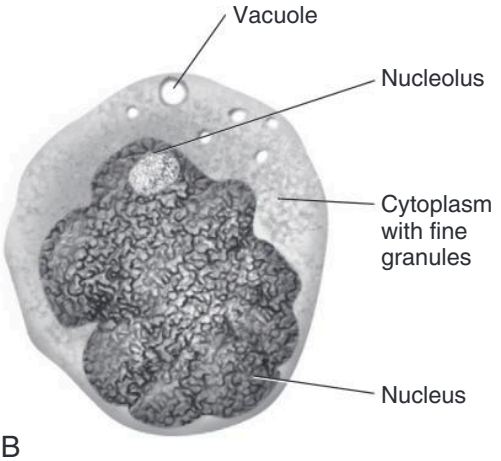


B

**FIGURE 8.4B** Schematic of promonocyte.

**SIZE:** 12 to 20 μm

**NUCLEUS:** Irregularly shaped; folded; may have brainlike convolutions
**Nucleoli:** May or may not be visible
**Chromatin:** Fine to lacy

**CYTOPLASM:** Light blue to gray
**Granules:** Fine azurophilic (burgundy colored)

**N:C RATIO:** 2:1 to 3:1

**REFERENCE INTERVAL:**
**Bone Marrow:** Less than 1%
**Peripheral Blood:** 0%

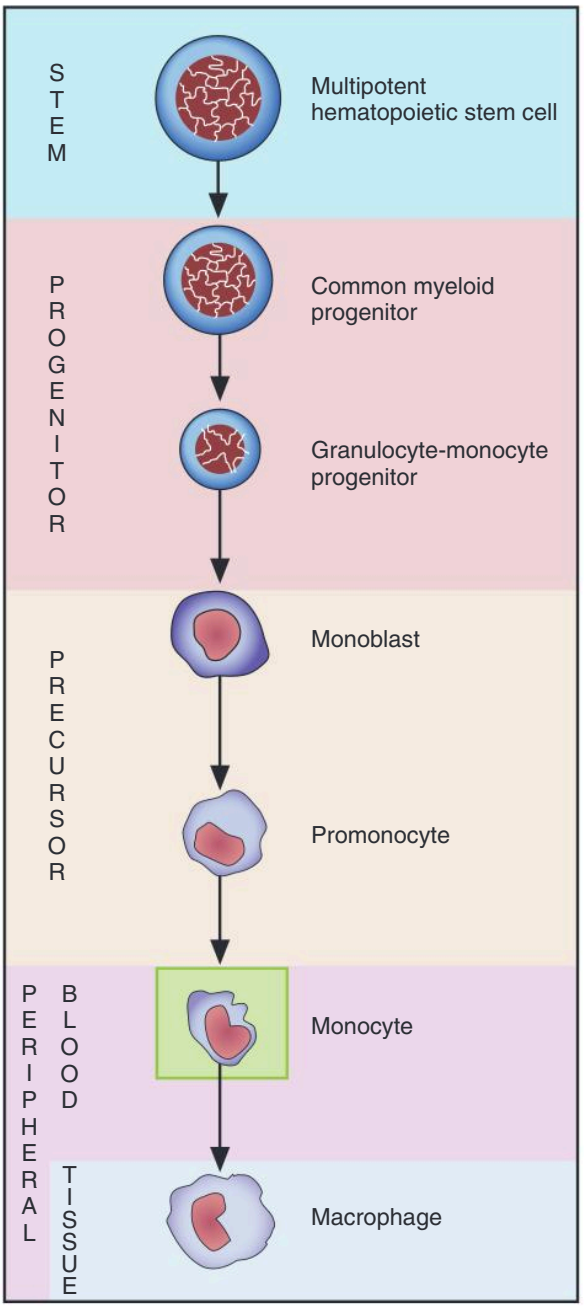


**FIGURE 8.5** Monocyte sequence: monocyte.

## MONOCYTE

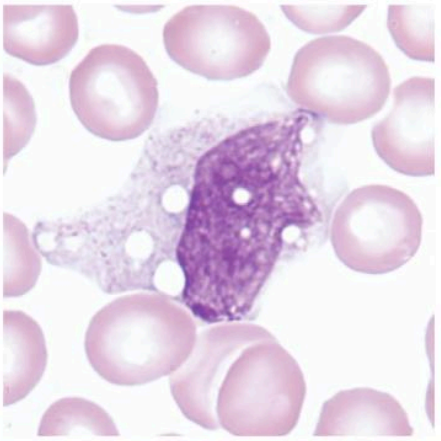

A

**FIGURE 8.6A** Monocyte.

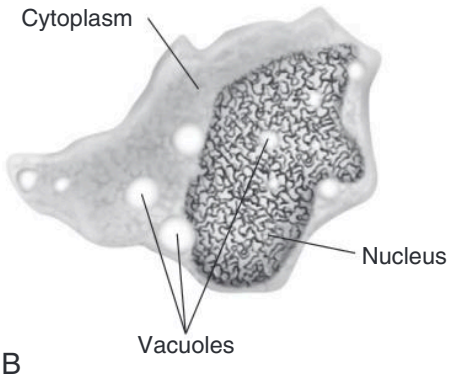


B

**FIGURE 8.6B** Schematic of monocyte.

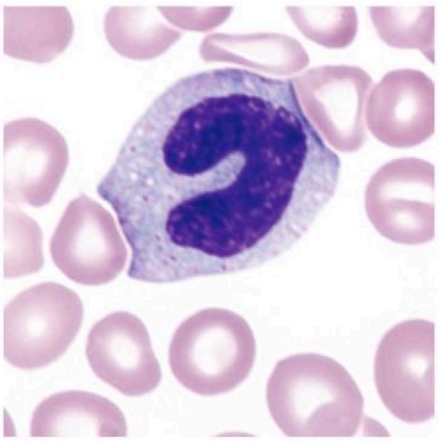

C

**FIGURE 8.6C** Monocyte without vacuoles.

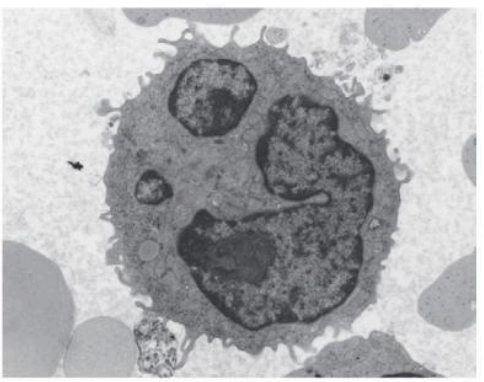

D

**FIGURE 8.6D** Electron micrograph of monocyte (×16,500). Specimens for electron microscopy are prepared by embedding tissue in a suitable medium, such as resin. Ultra-thin cross sections are then prepared. Because this image shows a cross section, the lobes of the nucleus appear to be separate, but are not.

**SIZE:** 12 to 20 μm

**NUCLEUS:** Variable; may be round, horseshoe shaped, or kidney shaped; often has folds producing brainlike convolutions
**Nucleoli:** Not visible
**Chromatin:** Lacy

**CYTOPLASM:** Blue-gray; may have pseudopods
**Granules:** Many fine granules frequently giving the appearance of ground glass
**Vacuoles:** Absent to numerous

**N:C RATIO:** Variable

**REFERENCE INTERVAL:**
**Bone Marrow:** 2%
**Peripheral Blood:** 3% to 11%

Refer to Table 1.1 for more examples.

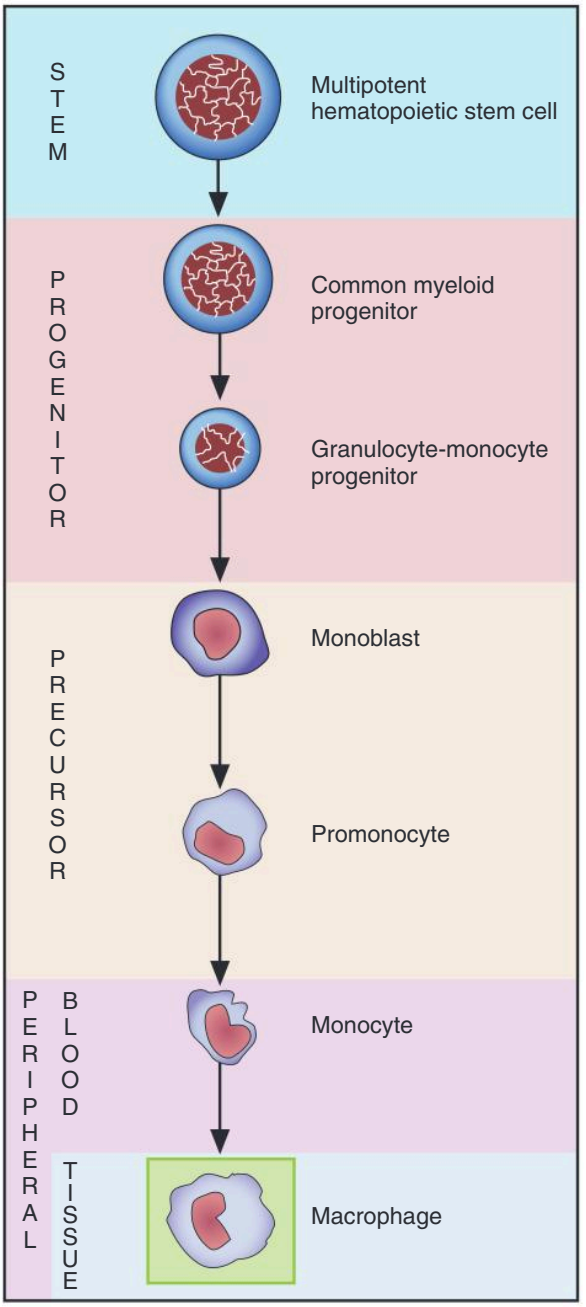


**FIGURE 8.7** Monocyte sequence: macrophage.

## MACROPHAGE

### Histiocyte

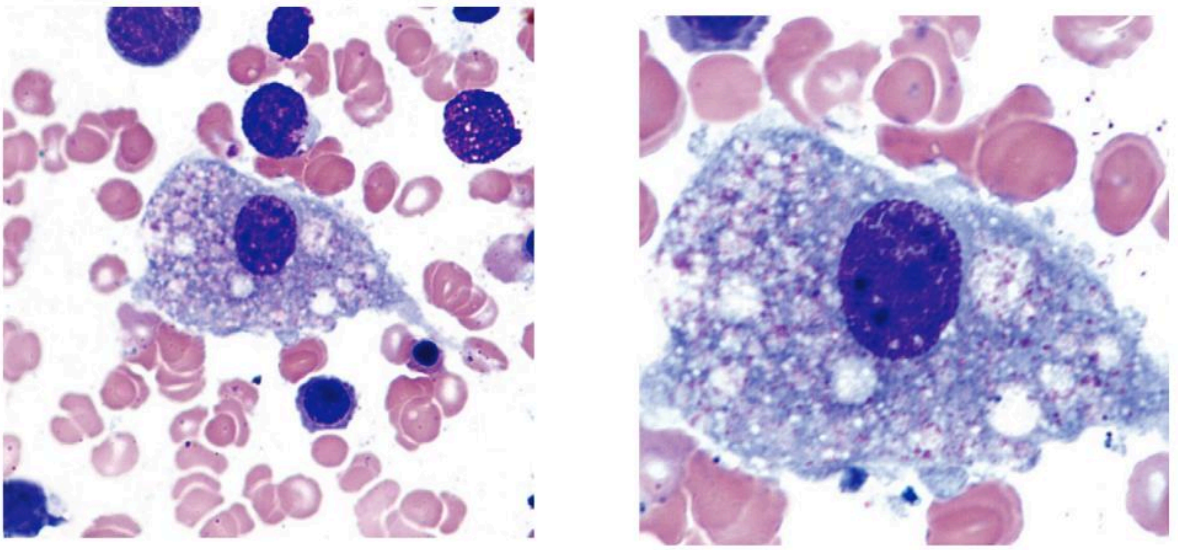

A B

**FIGURE 8.8** Macrophage. Bone marrow. (A) ×500; (B) ×1000.

**SIZE:** 15 to 80 μm

**NUCLEUS:** Eccentric, kidney- or egg-shaped, indented, or elongated
**Nucleoli:** 1 to 2
**Chromatin:** Fine, dispersed

**CYTOPLASM:** Abundant with irregular borders; may contain ingested material
**Granules:** Many coarse azurophilic (burgundy-colored)
**Vacuoles:** May be present

**REFERENCE INTERVAL:** Macrophages reside in tissues such as bone marrow, spleen, liver, lungs, and others. Rarely, seen in the peripheral blood during severe sepsis.

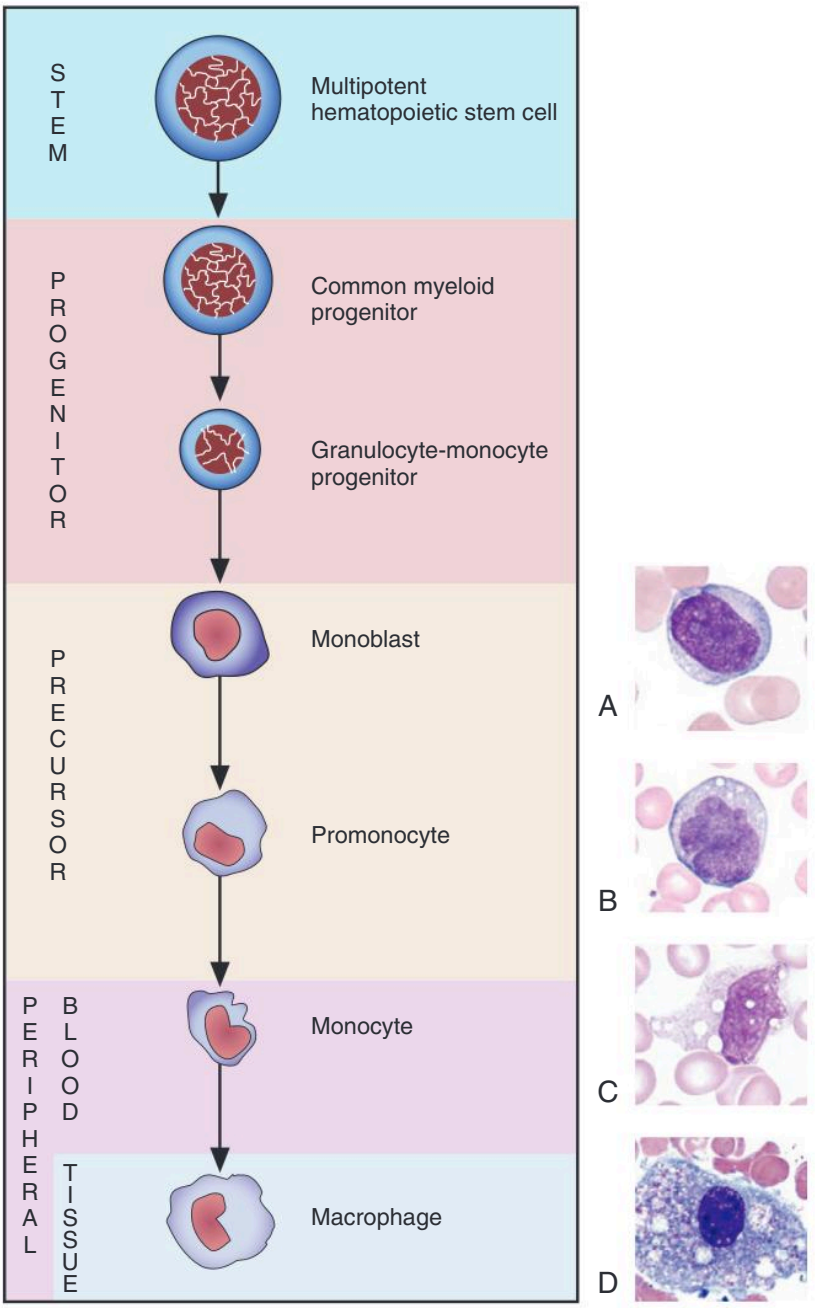


**FIGURE 8.9** Monocyte sequence with: (A) monoblast; (B) promonocyte; (C) monocyte; and (D) macrophage.